

LYTIC EPIPHYSEAL LESIONS

- TUMOR
 - Giant Cell Tumor
 - Chondroblastoma
 - Langerhans Cell Histiocytosis
 - Metastases and mieloma
 - Aneurysmal bone cyst
 - Osseous Lipoma
- OSTEOMYELITIS
- SUBCHONDRAL CYST (ARTHROPATHY)
- INTRAOSSEOUS GANGLION

GIANT CELL TUMOR

- Originates in the metaphysis
- Most are benign, but may metastasize to lung
- Rare before physeal fusion, most commonly between 20 and 40 years of age
- Typical lesion lytic geographic at the end of a long bone, without margin sclerosis. In the skeletally mature, the lesion extends to the subchondral bone

GIANT CELL TUMOR

- Most common sites: About the knee, distal radius and spine (sacrum or body of vertebra)
- Approximately 10% local recurrence rate, but can be higher with less aggressive surgery.
- Recurrent tumors behave more aggressively.

GIANT CELL TUMOR

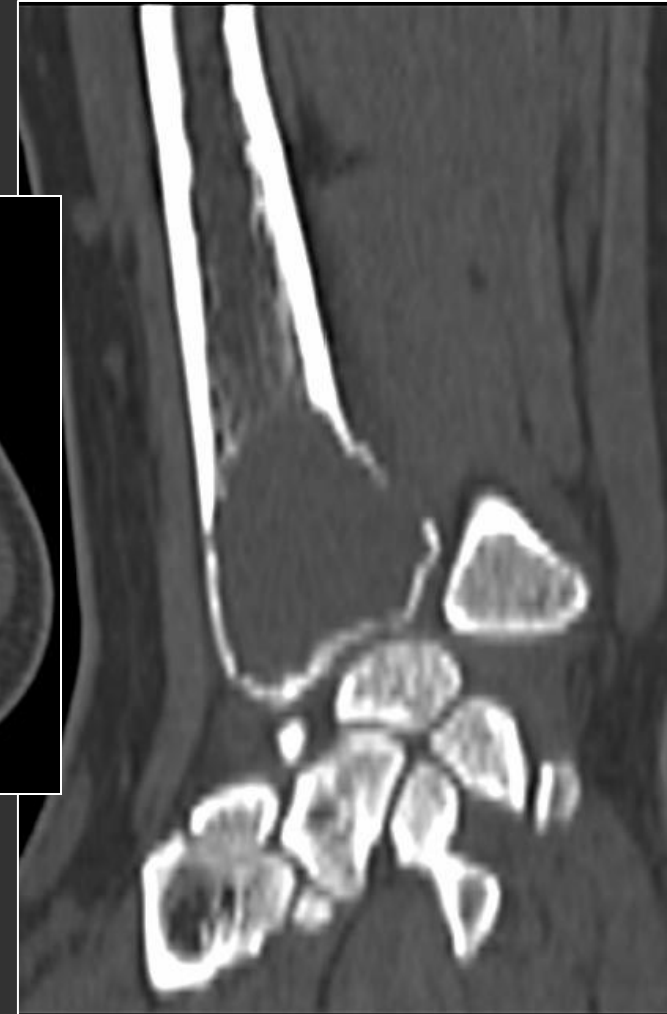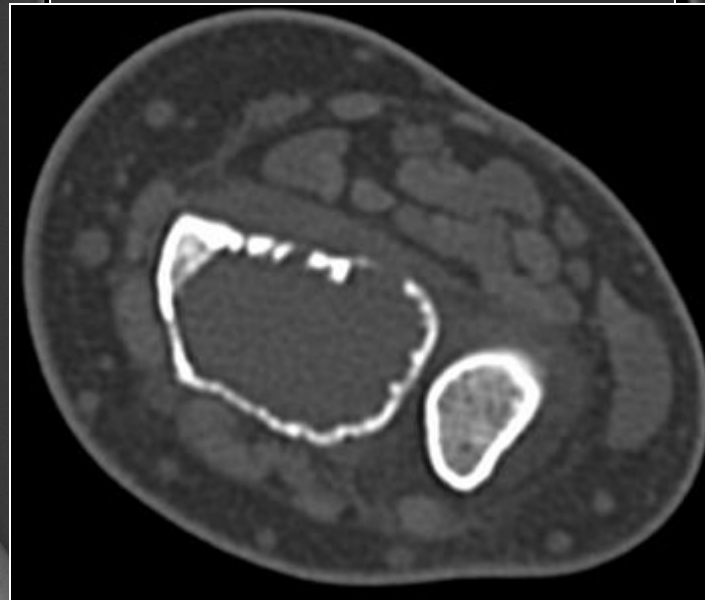
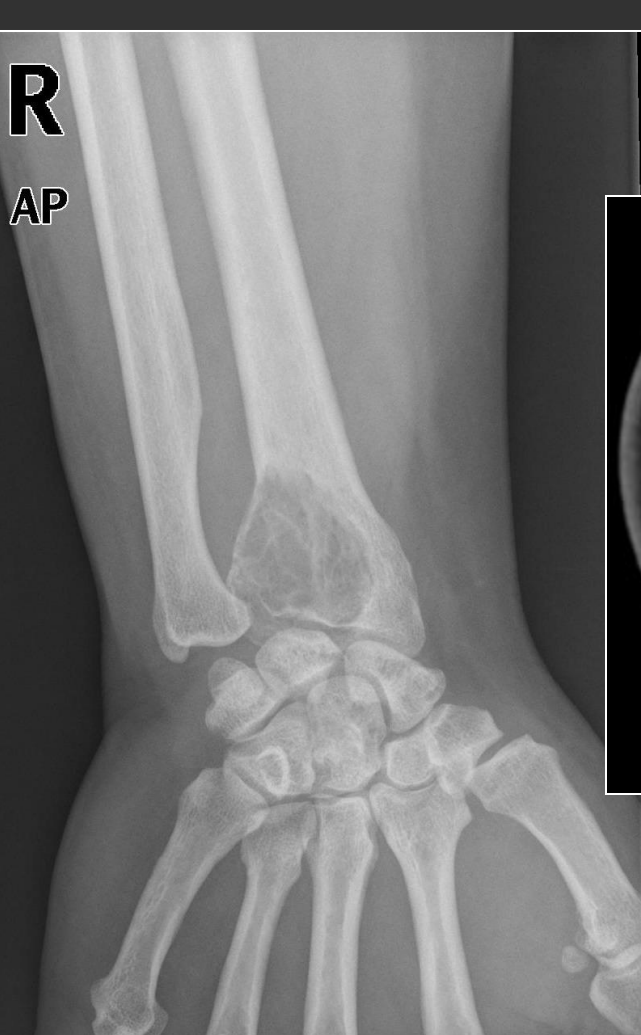- Helms uses four radiographic criteria for diagnosing GCT (“95% effective”):
 - GCT occurs only in patients with closed epiphyses
 - The lesion must be epiphyseal and abut the articular surface
 - GCT tumors are said to be eccentrically located in the bone
 - The lesion must have a sharply defined zone of transition that is not sclerotic
- Once one of the criteria is violated, the remainder don't even have to be used to eliminate a GCT!

GIANT CELL TUMOR

■ MRI

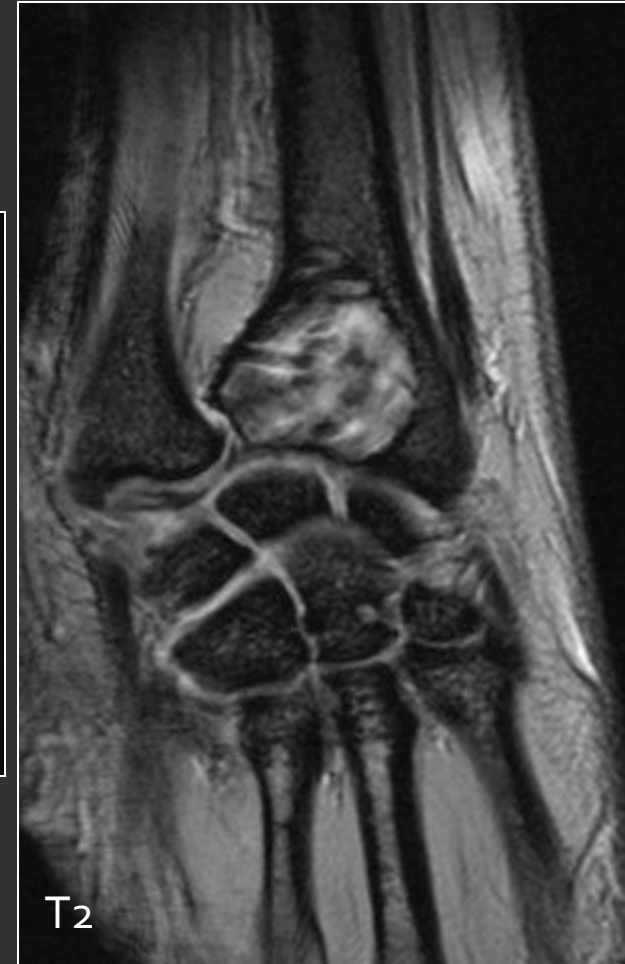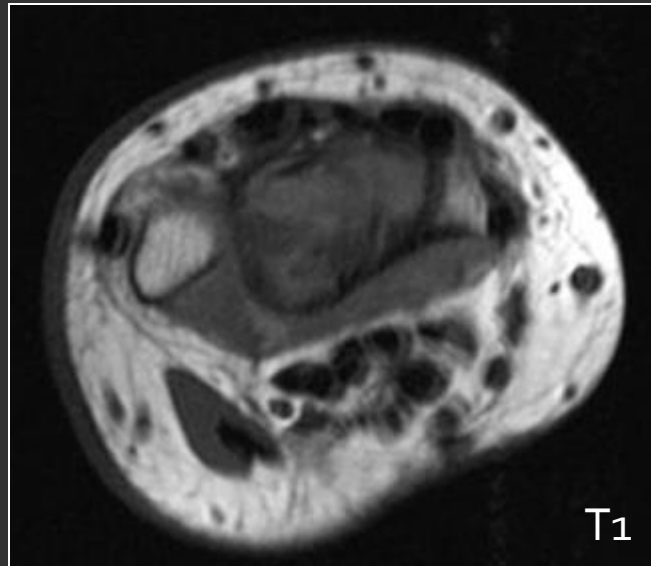
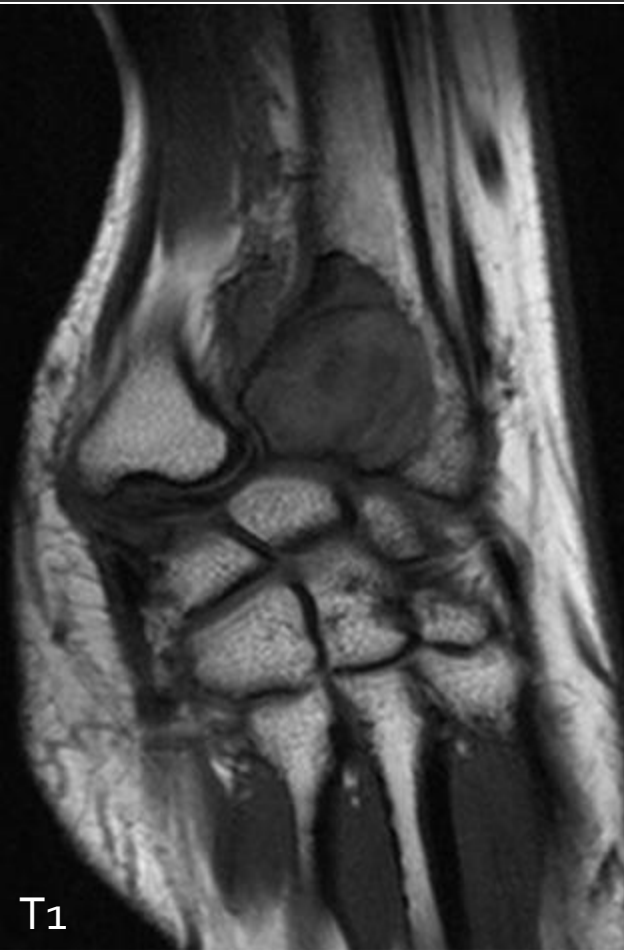- Uniform, intermediate-low signal intensity on T₁
- Enhance with intravenous gadolinium
- Often relatively low T₂ signal in nodular, zonal, whorled or uniform pattern – can help distinguish GCT from other common subchondral lesions such as subchondral cyst or a Brodie's abscess, which are usually uniformly bright
- Fluid-fluid levels also may be seen

GIANT CELL TUMOR – CASE 1 – Woman, 53 years



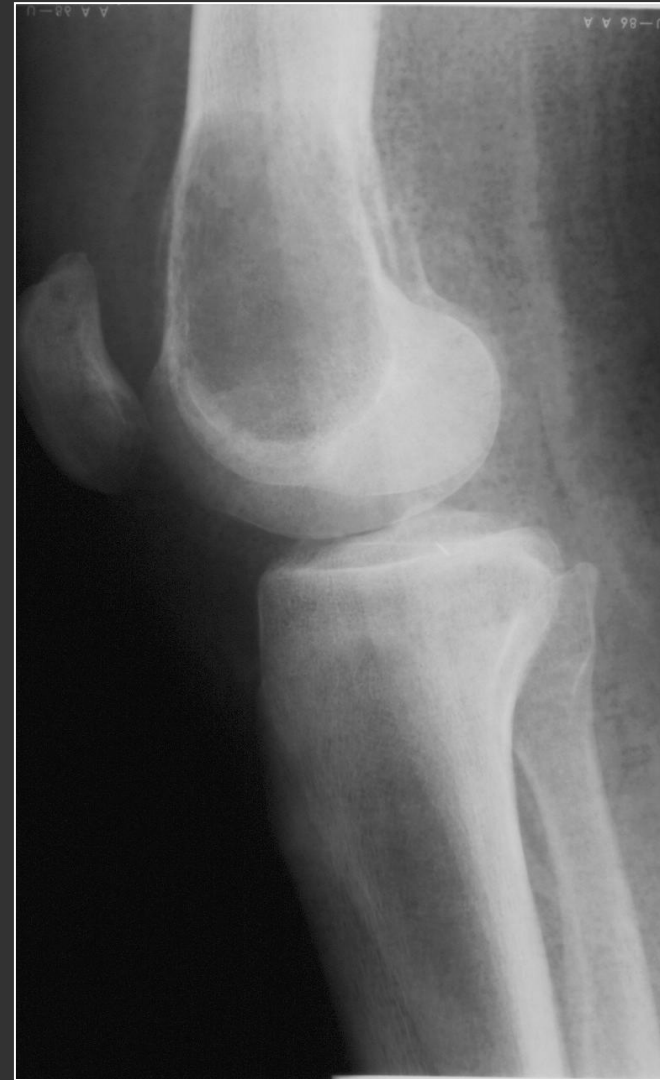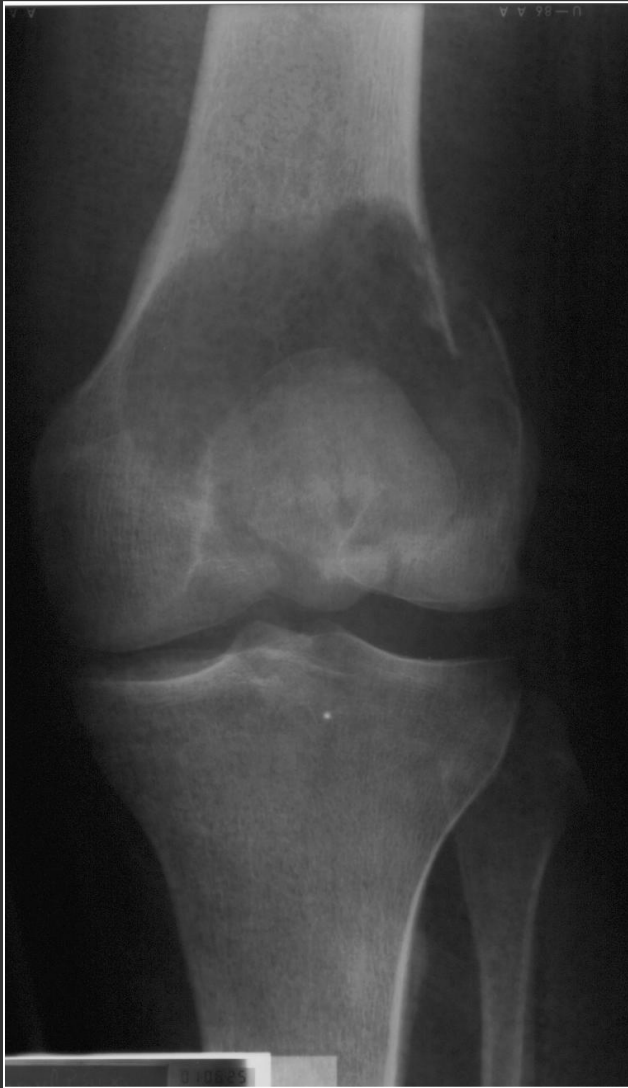X-ray and CT – Well-defined lytic lesion in the distal radius that has all four criteria typical for a giant cell tumor: (1) a well-defined but nonsclerotic zone of transition, (2) epiphyses are closed, (3) the lesion is eccentrically placed in the bone and (4) the lesion is epiphyseal and abuts the articular surface. CT shows cortical rupture (not seen at x-ray).

GIANT CELL TUMOR – CASE 1 – Woman, 53 years



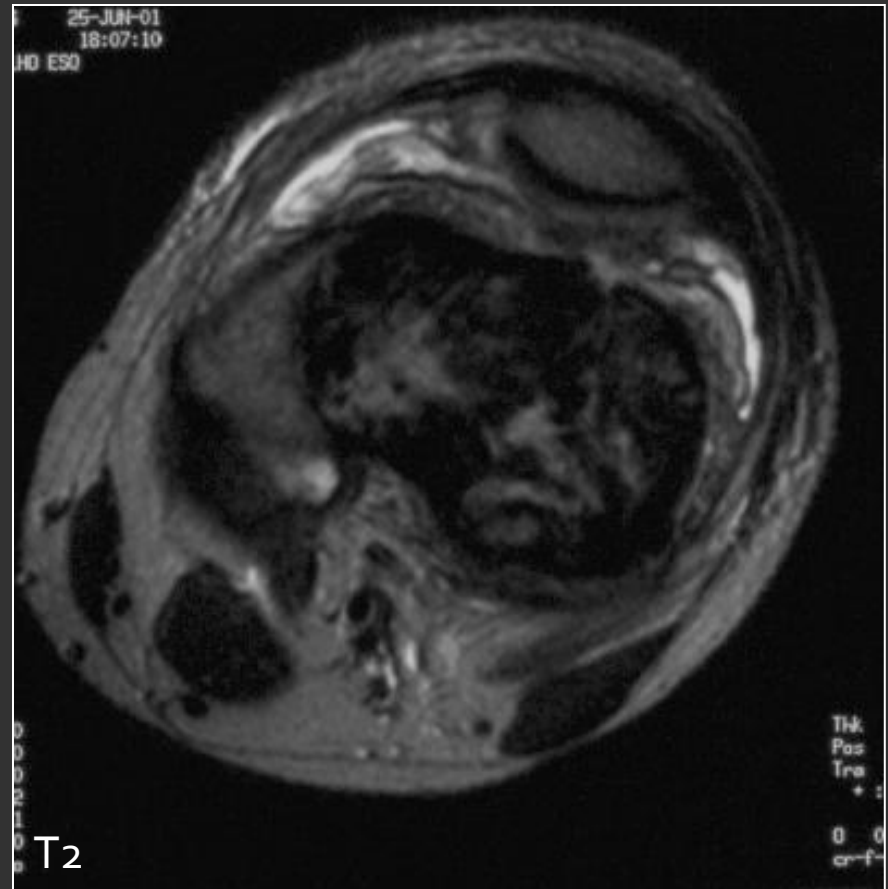
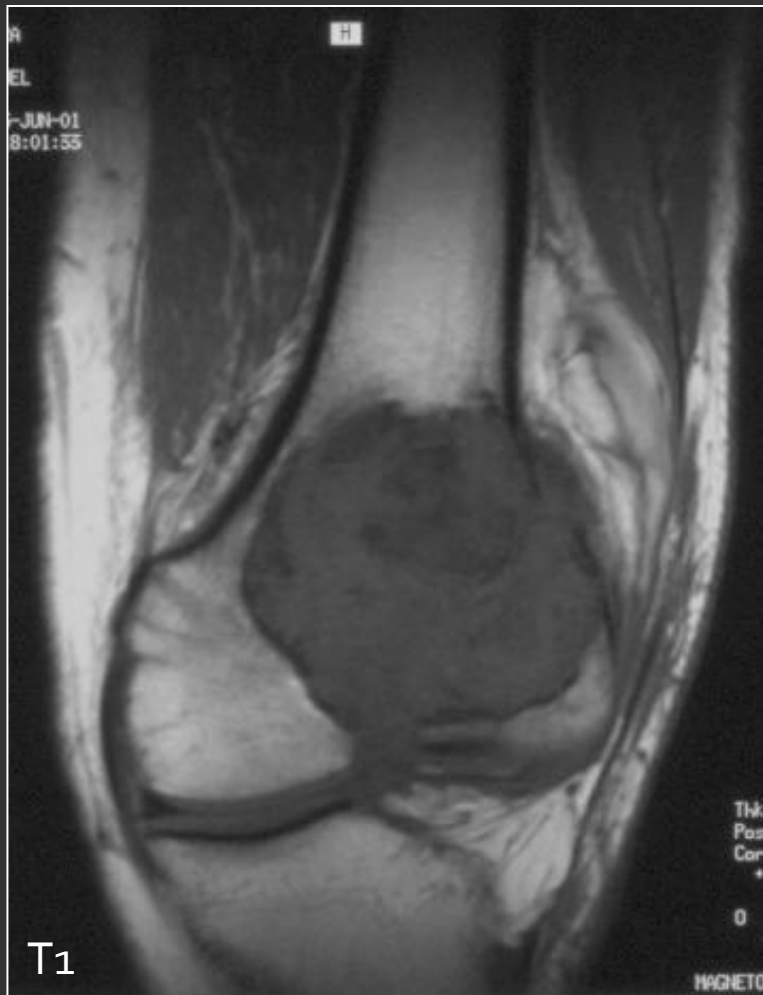MRI – The lesion has intermedium sign on T1. On T2 it is heterogeneous, with predominantly high signal, with some areas of low signal. There is no osseous edema neither soft tissue mass.

GIANT CELL TUMOR – CASE 2 – Man, 38 years



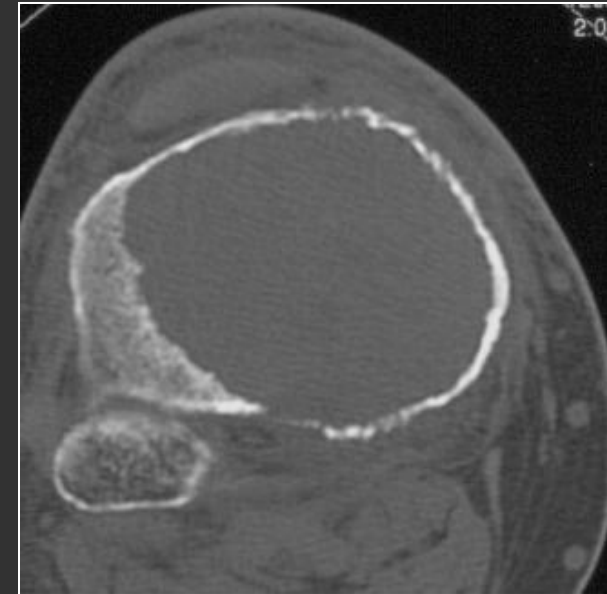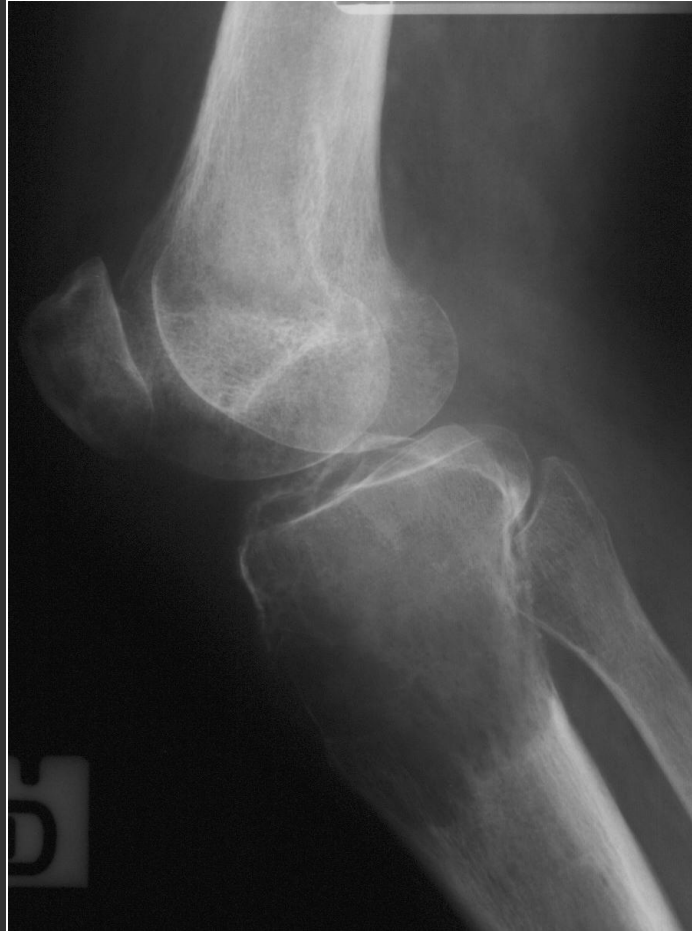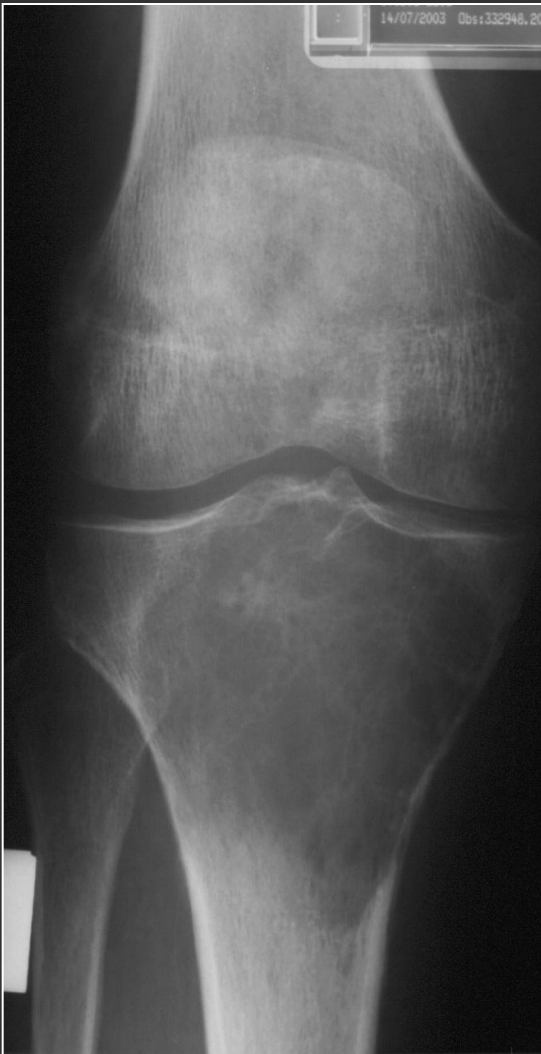X-Ray – Large lytic lesion in the distal femoral epiphysis, extending to the subchondral bone. There is no matrix and the zone of transition is narrow and lacks a sclerotic margin. This is a typical appearance and location of CGT.

GIANT CELL TUMOR – CASE 2 – Man, 38 years



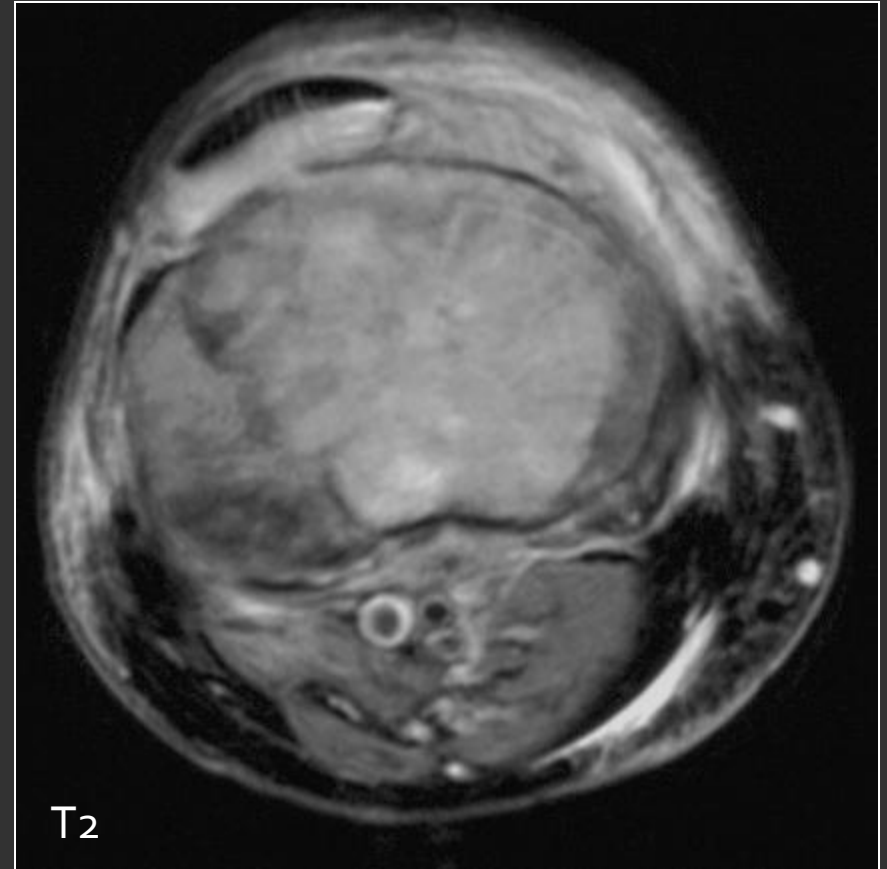
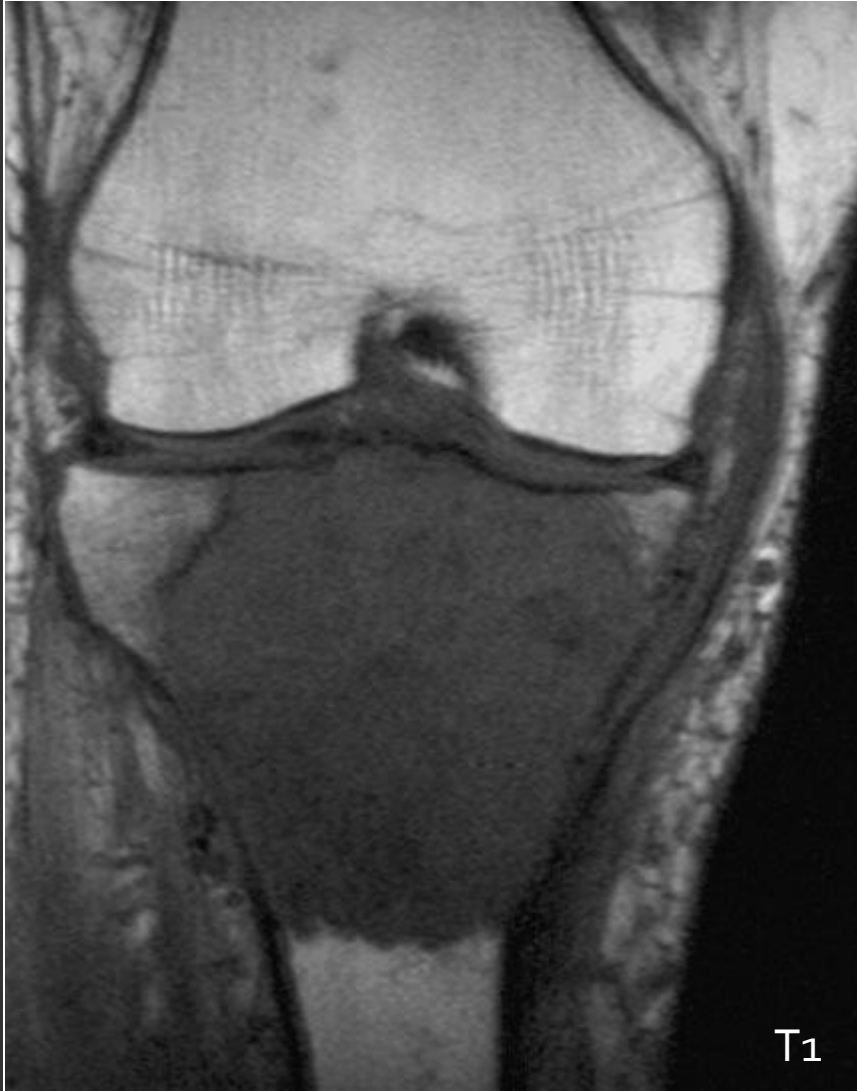MRI – The lesion has low signal on T₁ and also low signal on T₂ (although heterogeneous) in relation with abundant hemosiderin deposition. There is cortical rupture but no soft tissue mass.

GIANT CELL TUMOR – CASE 3 – Man, 70 years



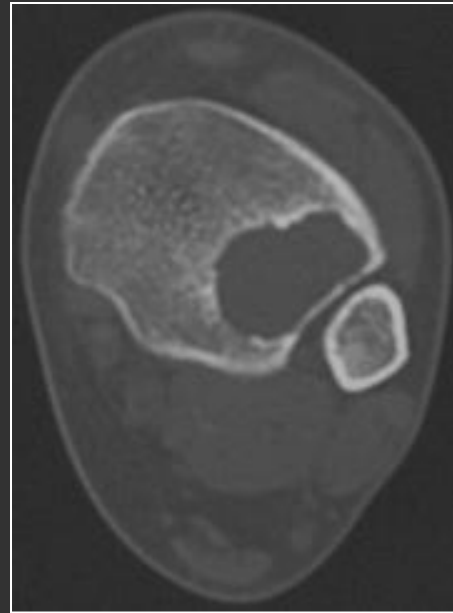
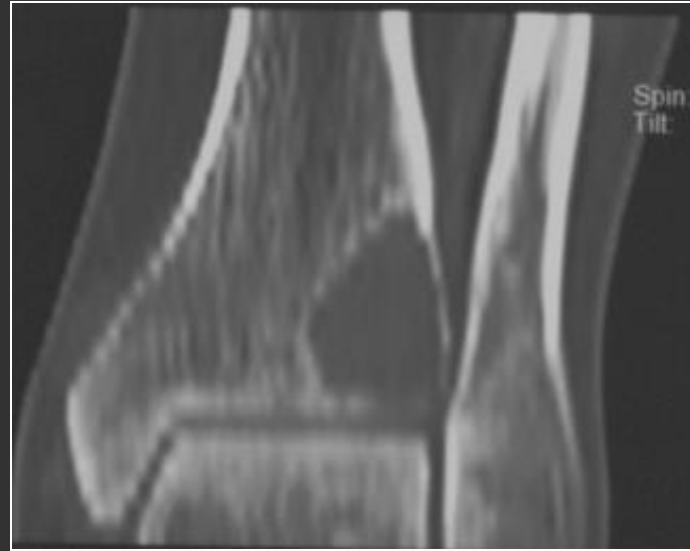
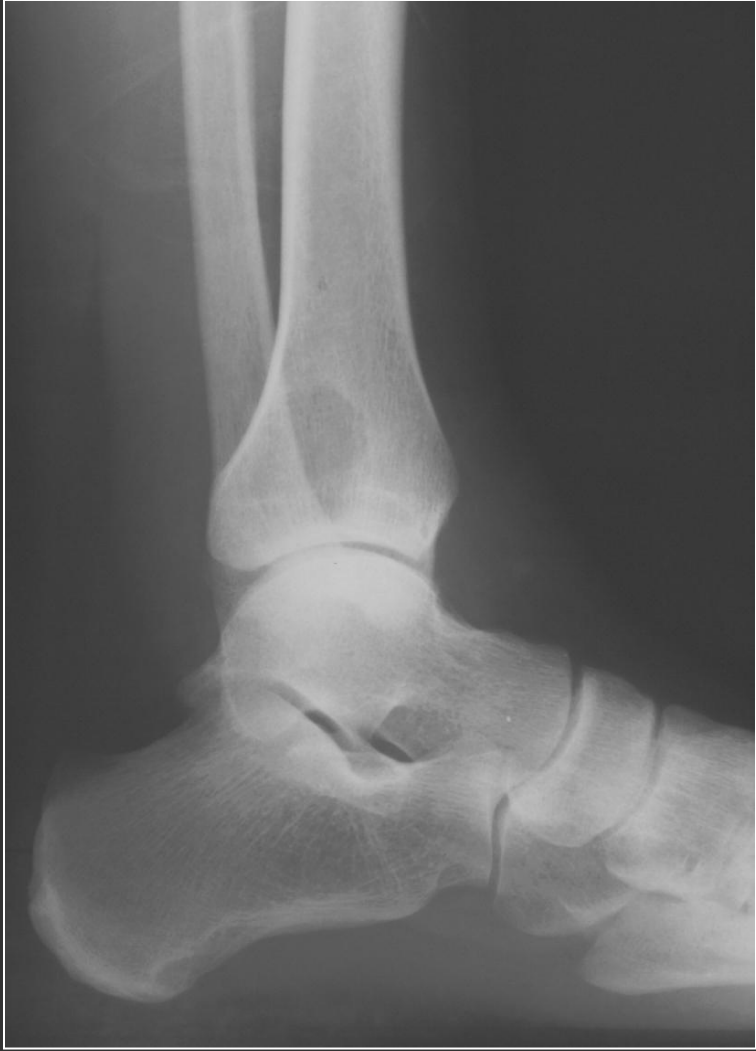X-Ray and CT – Lytic lesion of the proximal tibia (epiphysis and metaphysis). This patient is 70 years old, so metastase must be in differential diagnosis. However there was no known primary tumor and histology demonstrated GCT.

GIANT CELL TUMOR – CASE 3 – Man, 70 years



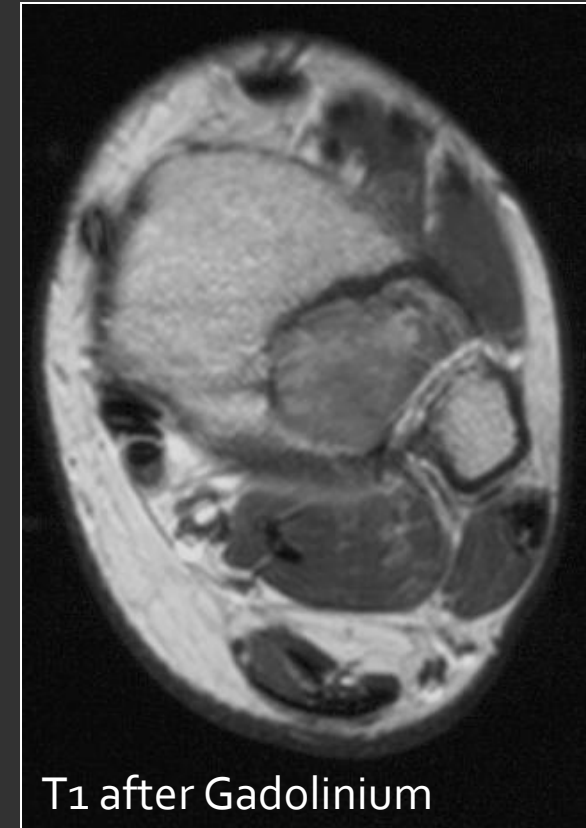
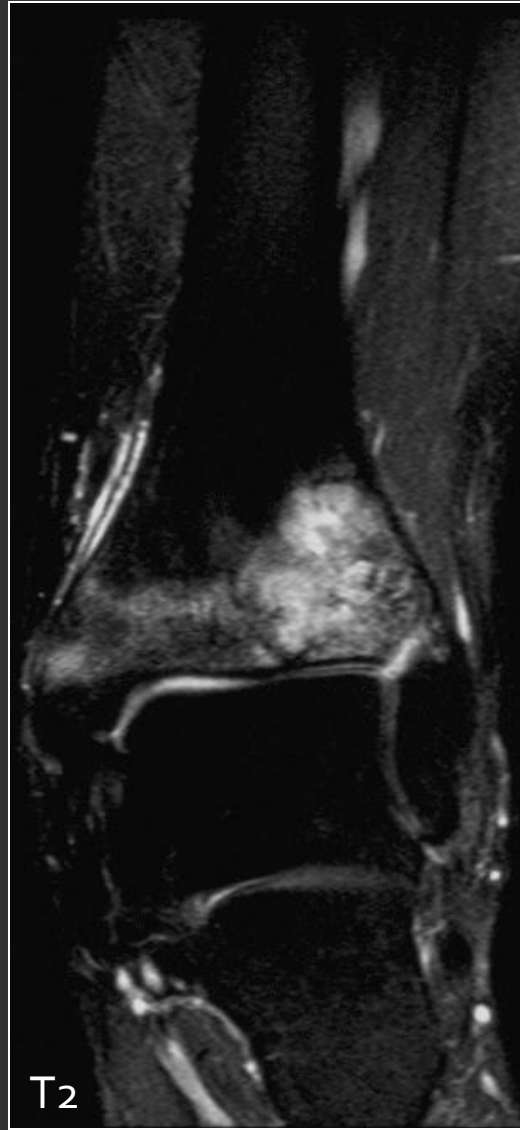
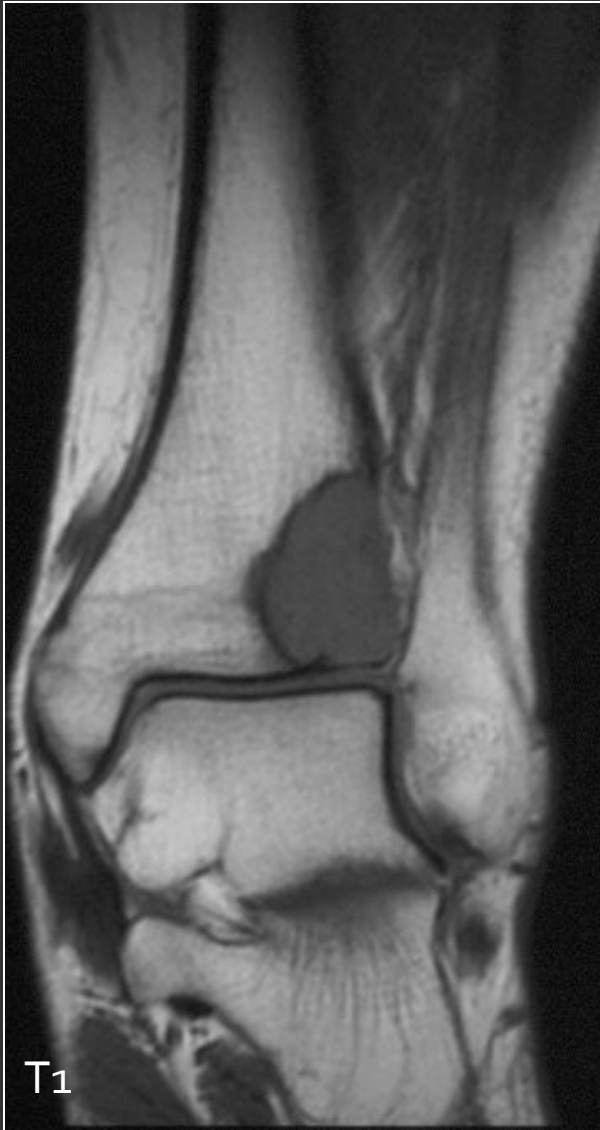MRI – The lesion is heterogeneous with low signal on T1 and high signal on T2. There is cortical thinning and rupture, perilesional edema and a small soft tissue mass anteriorly.

GIANT CELL TUMOR – CASE 4 – Man, 30 years



X-Ray and CT – Eccentric (lateral side), subarticular lytic lesion, of the distal epiphysis (and metaphysis) of tibia. This is another typical GCT that fills the four Helms' criteria.

GIANT CELL TUMOR – CASE 4 – Man, 30 years



MRI – The lesion has low signal on T1 and high signal on T2. There is cortical thinning, bone marrow and soft tissue edema and articular effusion, but no soft tissue mass. After gadolinium there is relatively homogeneous enhancement.

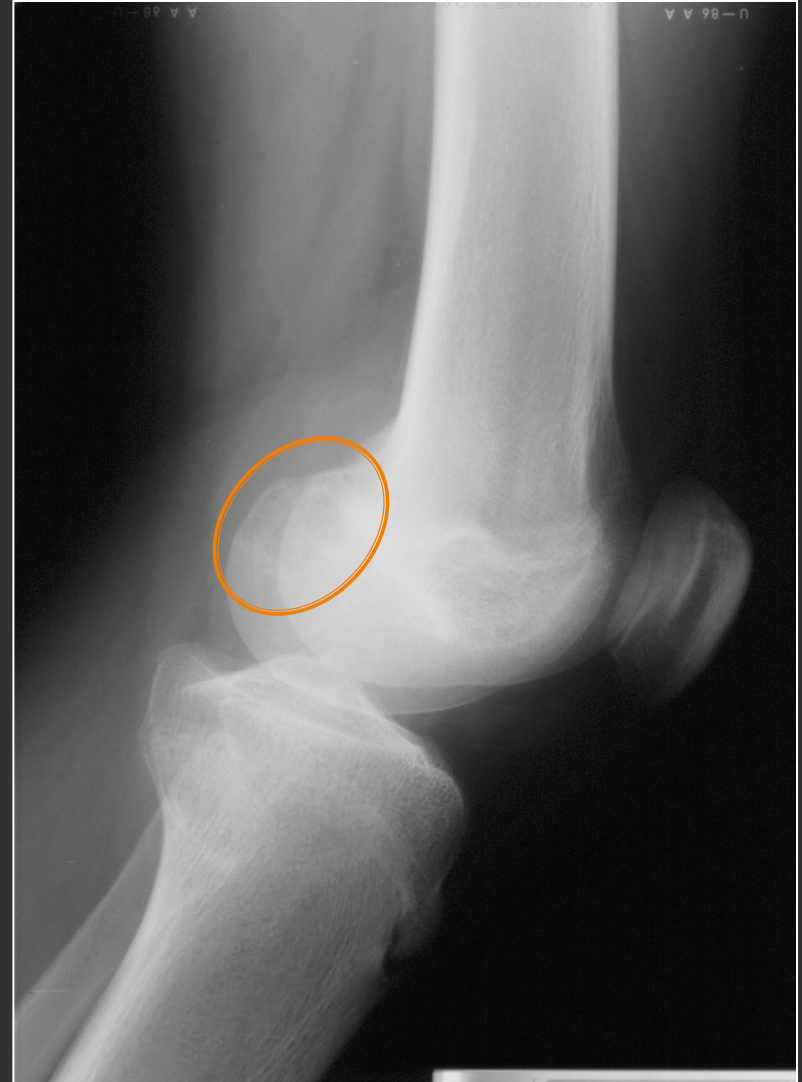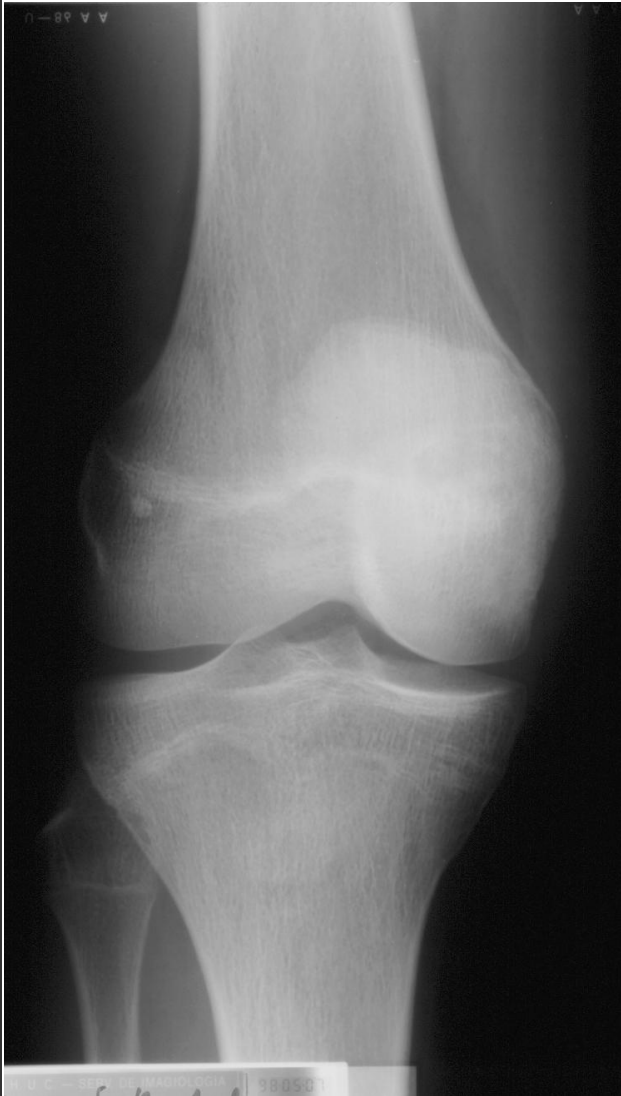CHONDROBLASTOMA

- Uncommon benign neoplasm that occurs almost exclusively in the epiphysis in immature skeleton (< 30 years old)
- Proximal humerus and around the knee are the most common locations
- The lesion typically has geographic and sclerotic margins
- The tumor is predominately lytic, although chondroid matrix is present in 50% of cases
- May elicit prominent periosteal reaction in the metaphysis (remote from the lesion)

CHONDROBLASTOMA

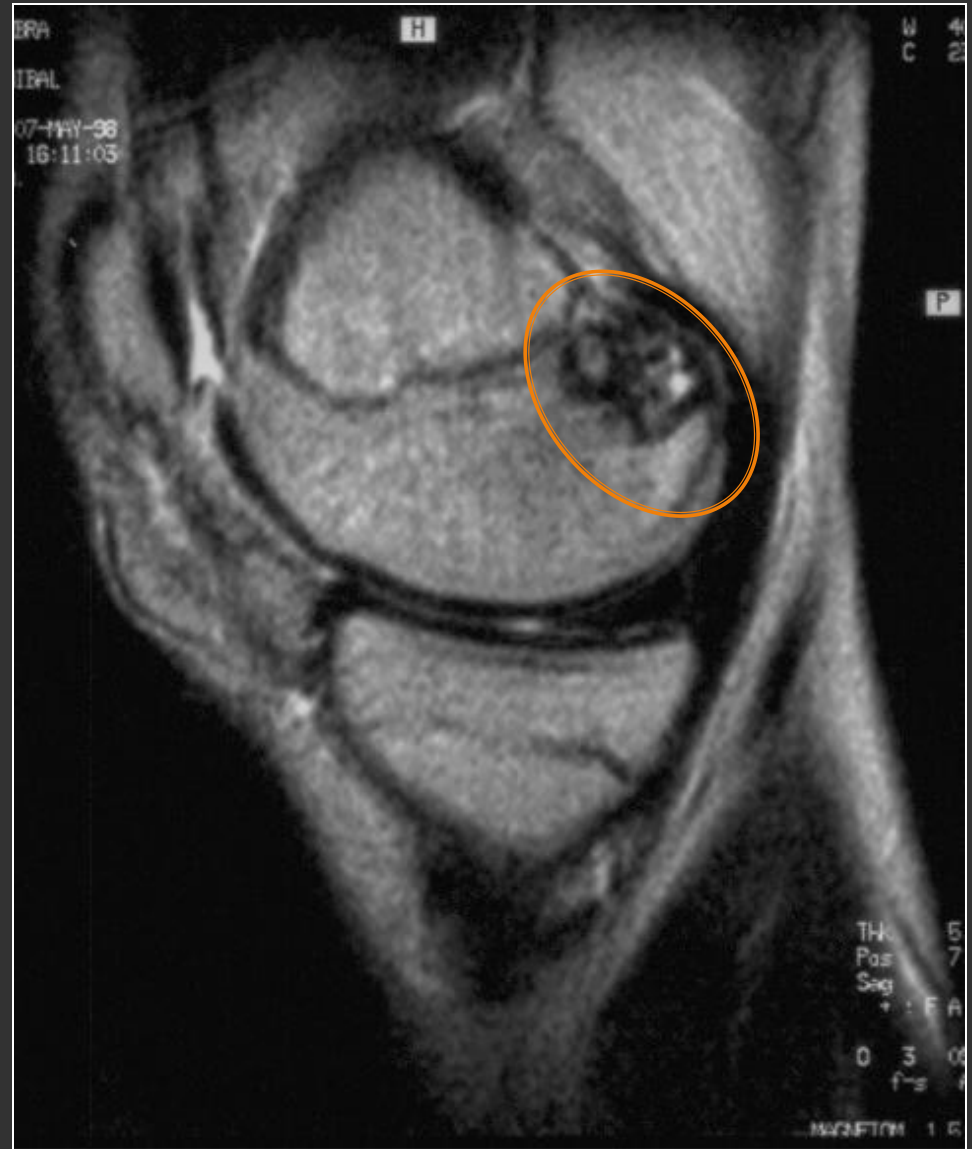
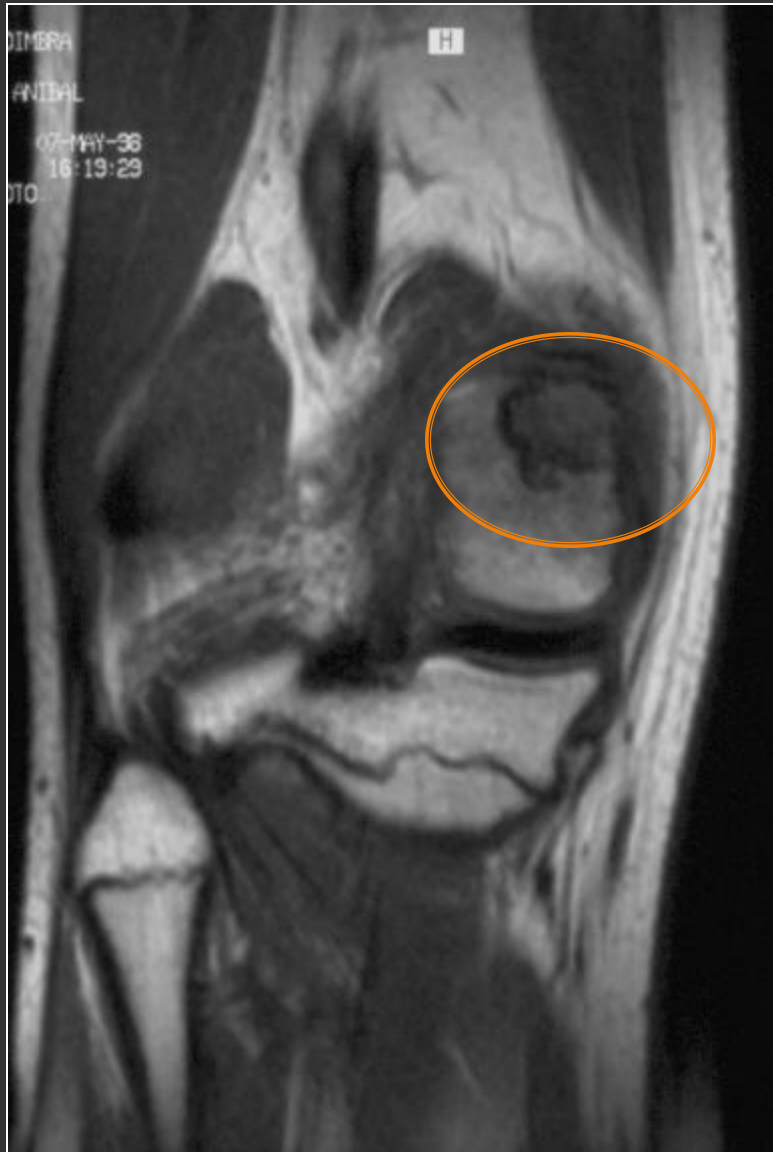
- MRI
 - Isointense with muscle on T₁
 - Intermediate heterogeneous to high signal intensity on T₂
 - Often in a lobulated pattern
 - Intense bone marrow and adjacent soft tissue edema, suggesting a more aggressive lesion than is demonstrated by radiography

CHONDROBLASTOMA – CASE 1 – Man, 18 years



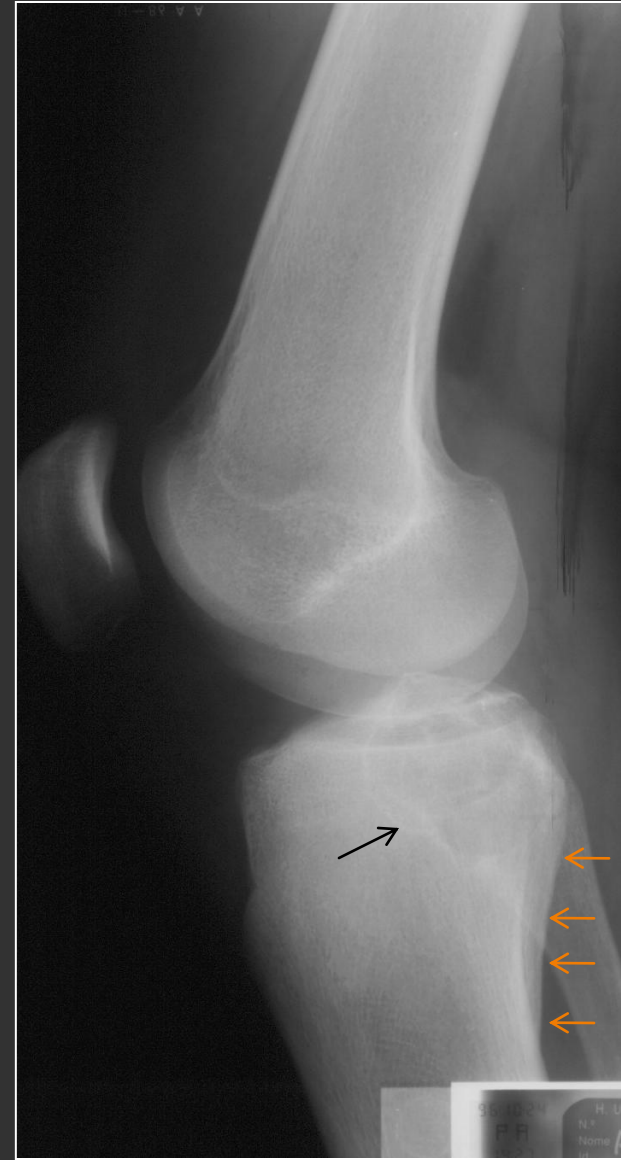
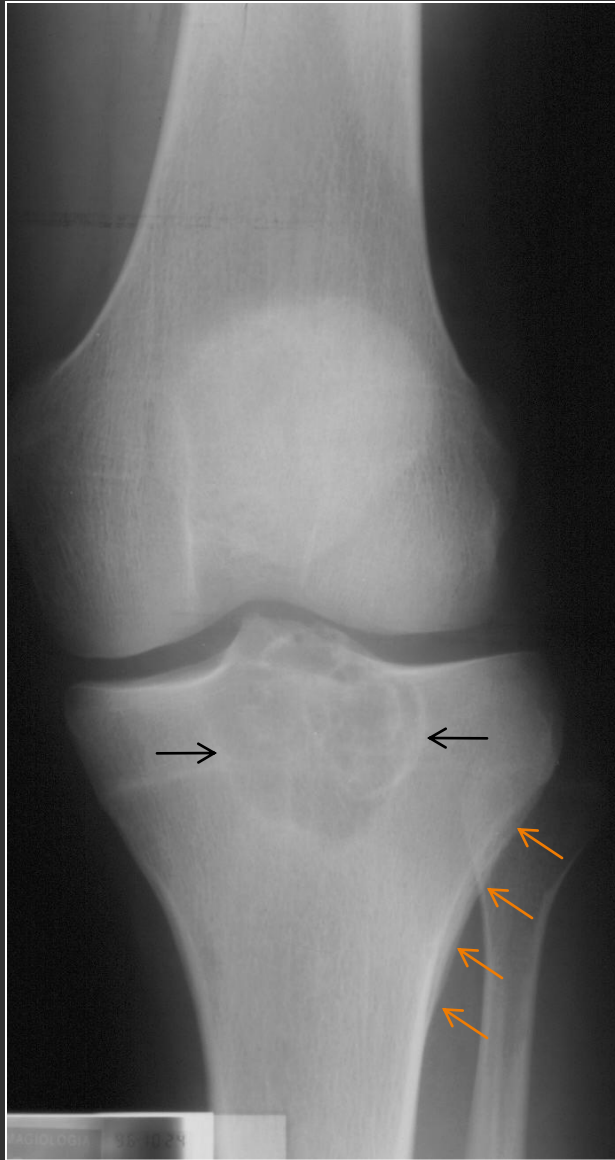
X-Ray – AP radiograph of the Knee is normal. However lateral radiograph shows a very subtle geographic lytic lesion in the posterior epiphysis (*circle*).

CHONDROBLASTOMA – CASE 1 – Man, 18 years



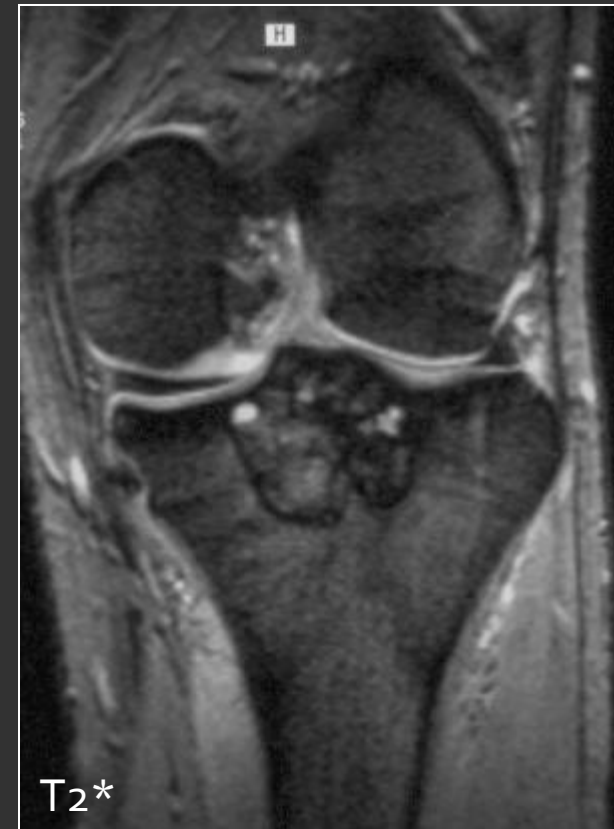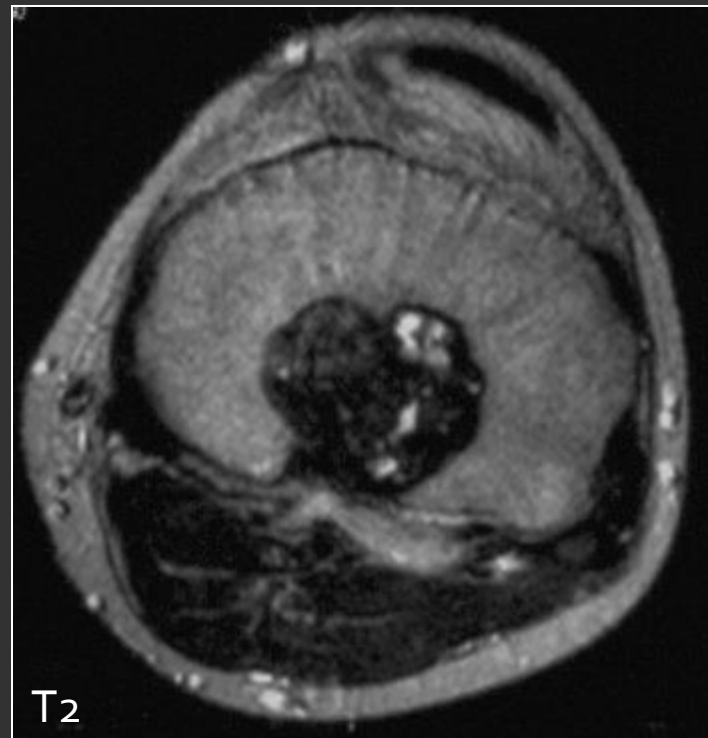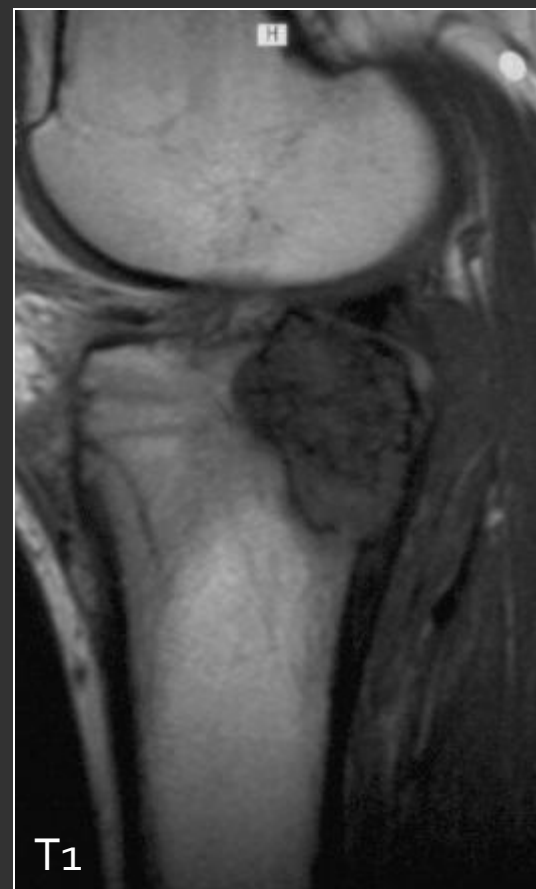
MRI – Here we can see that the lesion is located in medial condyle (postero-superior position) of the distal epiphysis of femur. The lesion has lobulated margins and is isointense with muscle on T1 and on T2 it is heterogeneous with areas of high signal. There is marked peritumoral edema. The findings are typical for chondroblastoma.

CHONDROBLASTOMA – CASE 2 – Man, 19 years



X-Ray - Central, lytic lesion located at the proximal epiphysis (and metaphysis) of tibia. The lesion has geographic and sclerotic margins (*black arrows*). Note the very dense, mature periosteal reaction in the metaphysis (*orange arrows*), remote from the tumor. Radiological findings and the age of patient are very typical for chondroblastoma.

CHONDROBLASTOMA – CASE 2 – Man, 19 years



MRI – The lesion is located in the epiphysis in a central and posterior position. It has intermediate signal on T1 with a lobular pattern, on T2 it is predominantly low signal, containing some small areas of high signal. There is edema of the muscles in contact with the tumor and periosteal reaction in posterior metaphysis. MRI appearance is also suggestive of chondroblastoma. **Remember, giant cell tumor usually is eccentric and the margin is not sclerotic.**

LANGERHANS CELL HISTIOCYTOSIS

- Rare spectrum of disorders related to histiocytic infiltration of various organ systems
- Letterer-Siwe disease: Aggressive multi-organ system disease, age 0-2 years, high mortality rate.
- Hand-Schüller-Christian disease: Intermediate, chronic multi-organ system disease
- Eosinophilic granuloma of bone: Single organ system involvement in bone

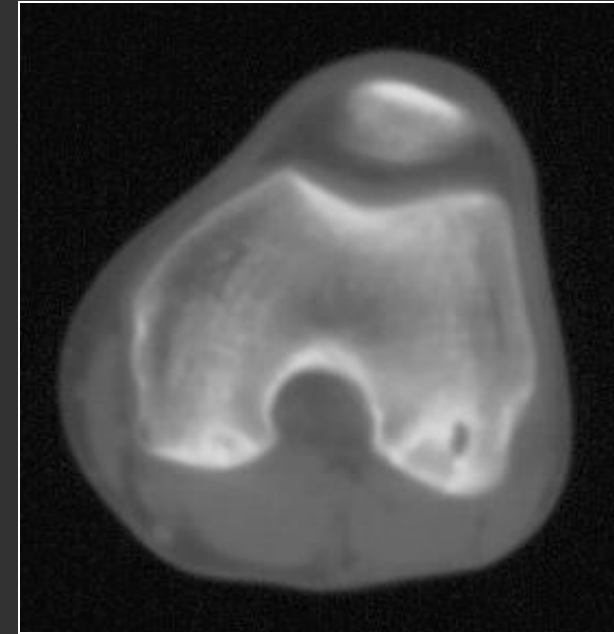
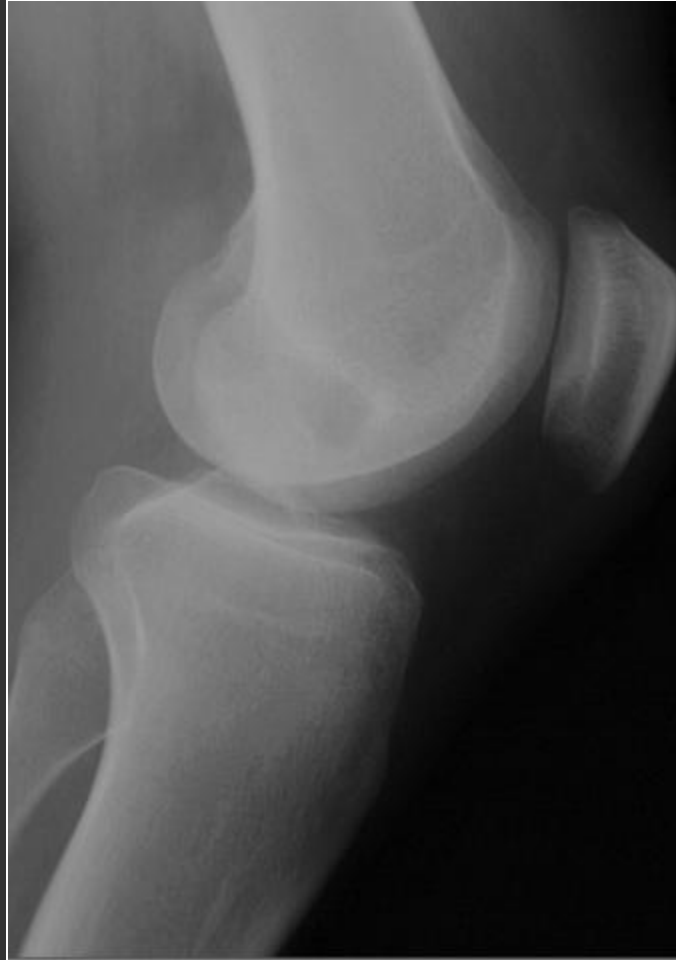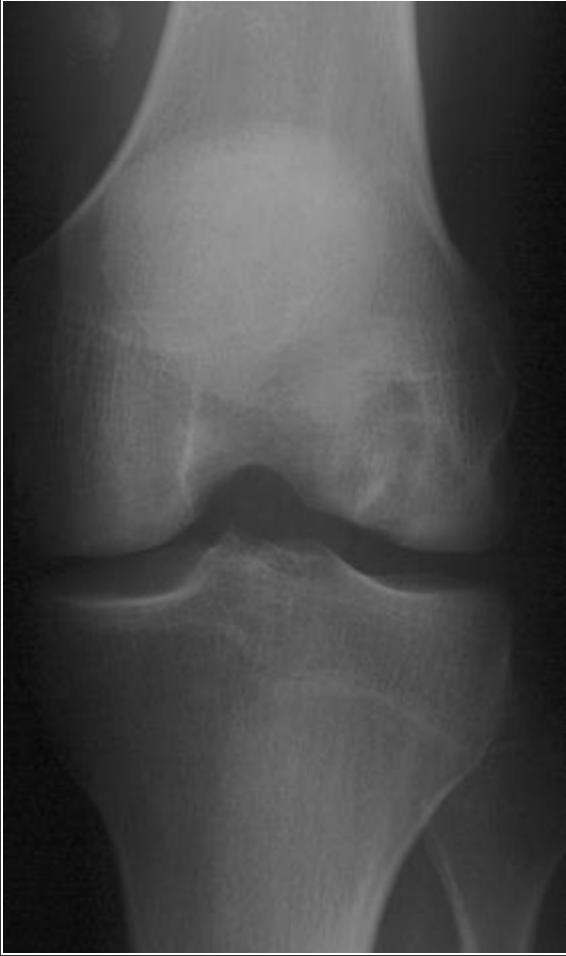LANGERHANS CELL HISTIOCYTOSIS

- Bone lesions may have a variety of appearances: it can be blastic or lytic, well or ill defined, have or not have a sclerotic border, may or may not elicit a periosteal response, with or without a soft tissue mass, with or without bone sequestrum...
- One classic pattern of long bone lesions begins with a highly aggressive moth-eaten or permeative pattern and soft tissue mass, but usually heal spontaneously over 6-24 months. The margin becomes well defined and periosteal reaction becomes solid.

LANGERHANS CELL HISTIOCYTOSIS

- These lesions are usually central and metadiaphyseal, but any part of the bone (including epiphysis) may be involved
- Difficult to exclude LCH from almost any differential of a bony lesion
- Patients must be younger than 30 years
- 10 – 20 % polyostotic
- Spine: *Vertebra plana*
- Skull: Beveled edge sharply defined lytic lesion

EOSINOPHILIC GRANULOMA – Man, 21 years



X-Ray and CT - This small lesion is difficult to detect and describe in the radiographic studies whereas in CT it's easier to identify the small lytic focus in the posterior surface of the left lateral femoral condyle.

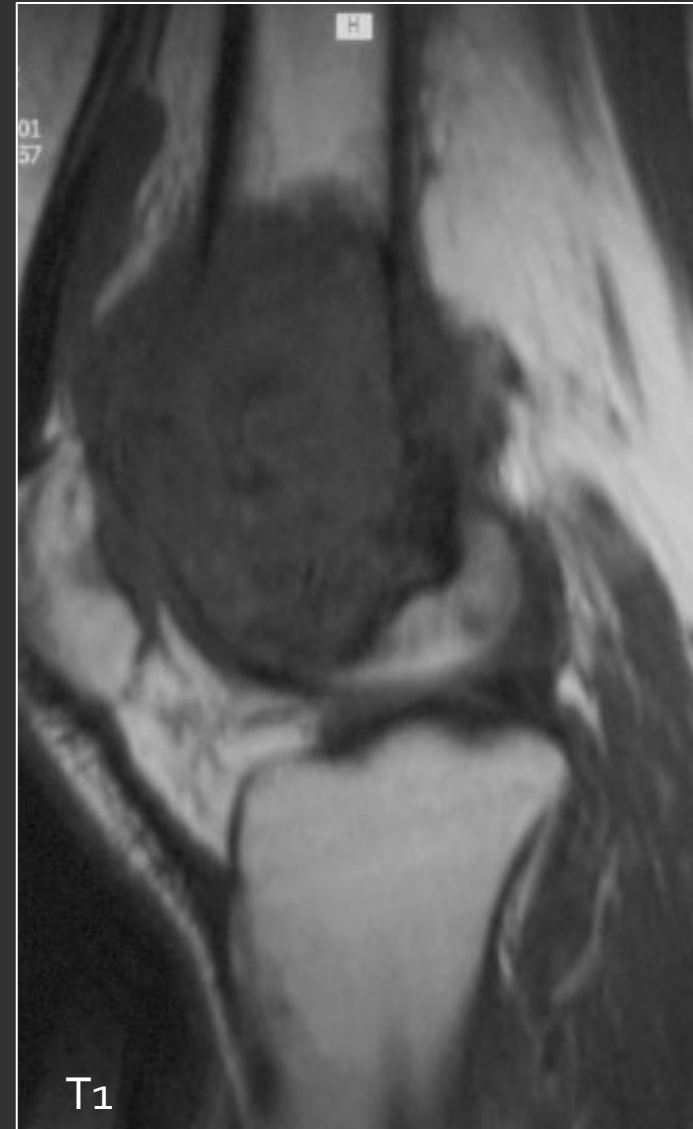
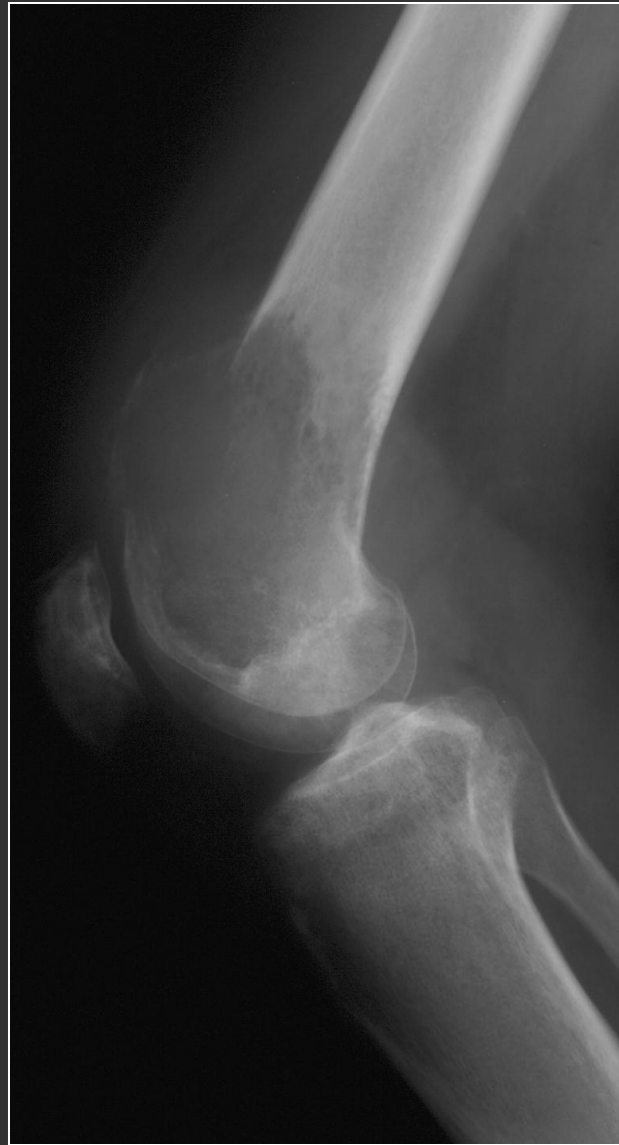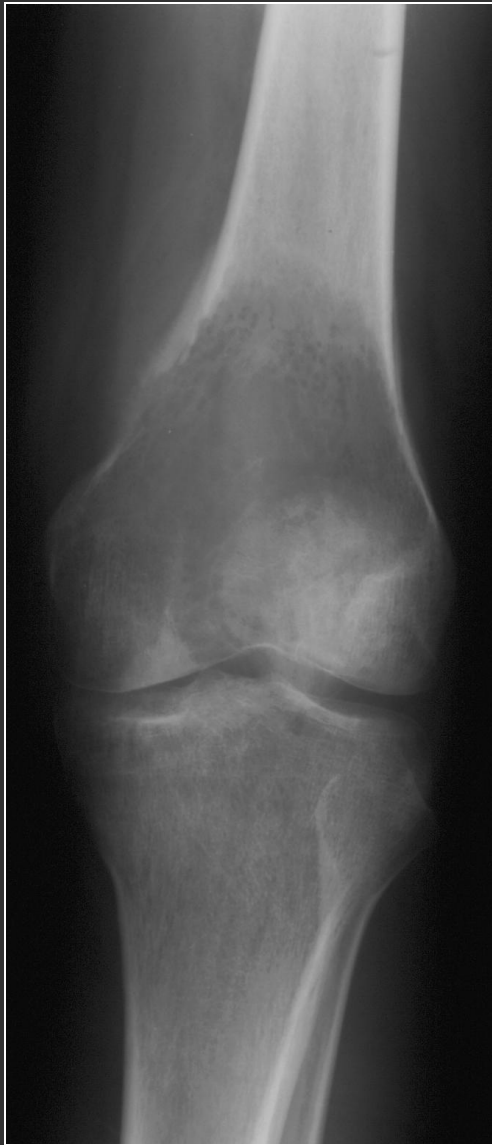METASTATIC DISEASE OF BONE

- More common than primary bone tumors
- 80% arise from primary tumors of the lung, breast, prostate and kidney
- Usually have a moth-eaten or geographic pattern with an ill-defined or wide zone of transition, no sclerotic margin and often little periosteal reaction or soft tissue mass
- Occasionally may present as a geographic, bubbly, expansile mass
- The density of metastases varies: can be purely lytic, blastic or mixed lytic and blastic

METASTATIC DISEASE OF BONE

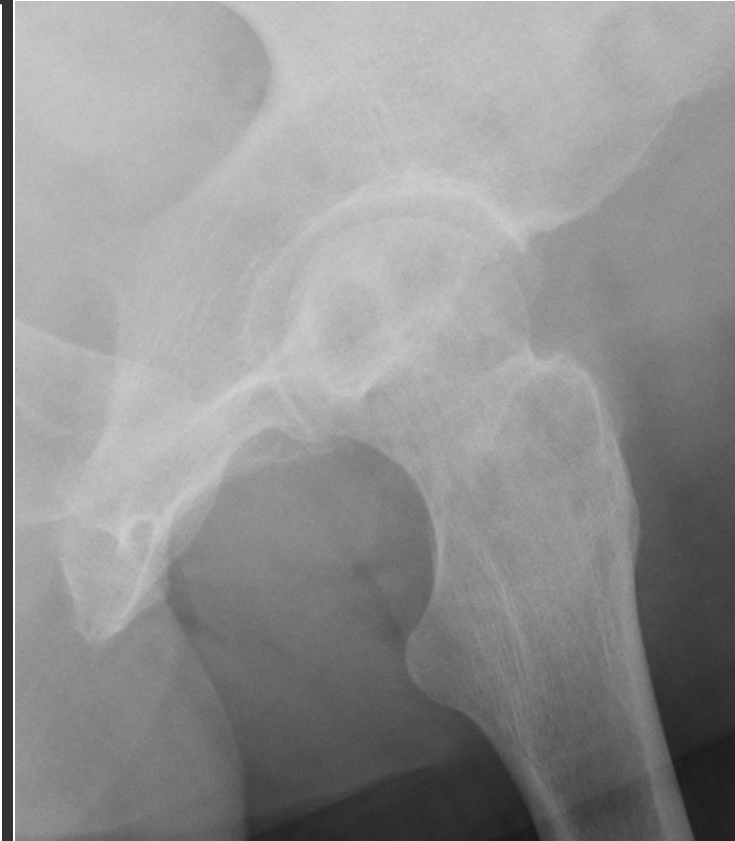
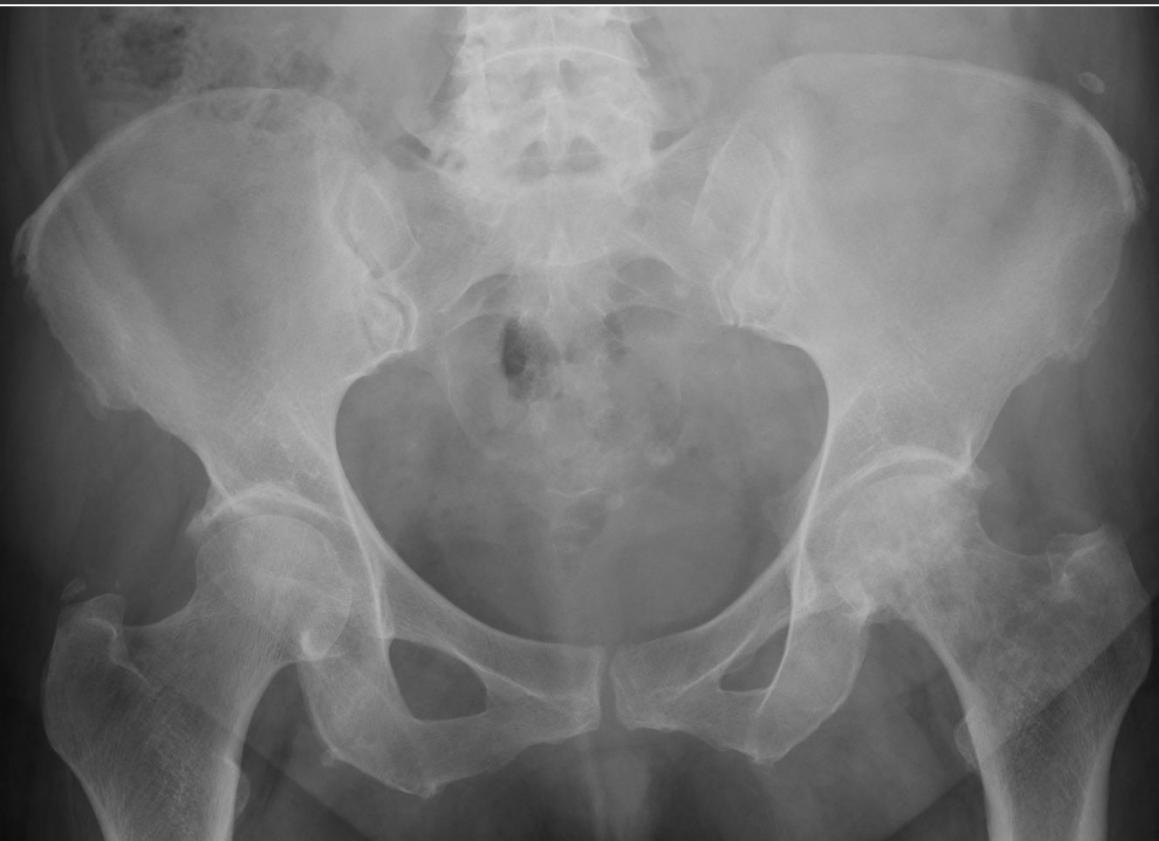- Most metastases occur where bone marrow is found – 80% are located in the axial skeleton and proximal humerus and femur
- Epiphyseal involvement, although not frequent, can occur
- The diagnosis is straightforward if numerous lesions are noted
- Helms says that metastatic disease should be considered for any lytic lesion – benign or aggressive in appearance – in a patient older than 40 years

OSSEOUS METASTASIS – CASE 1 - Man, 63 years



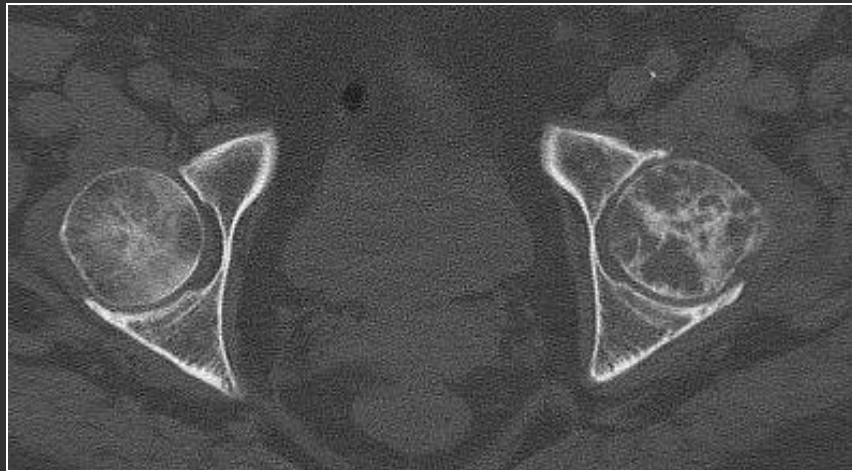
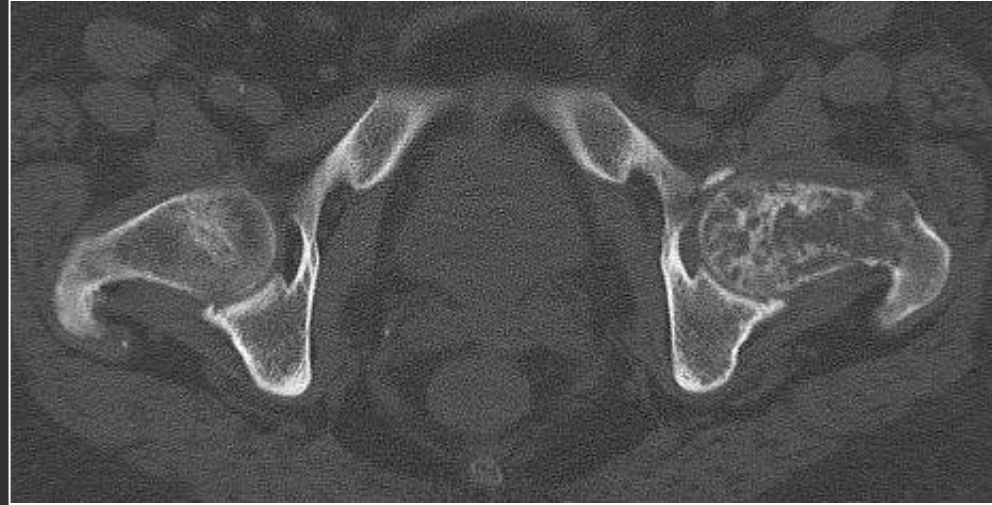
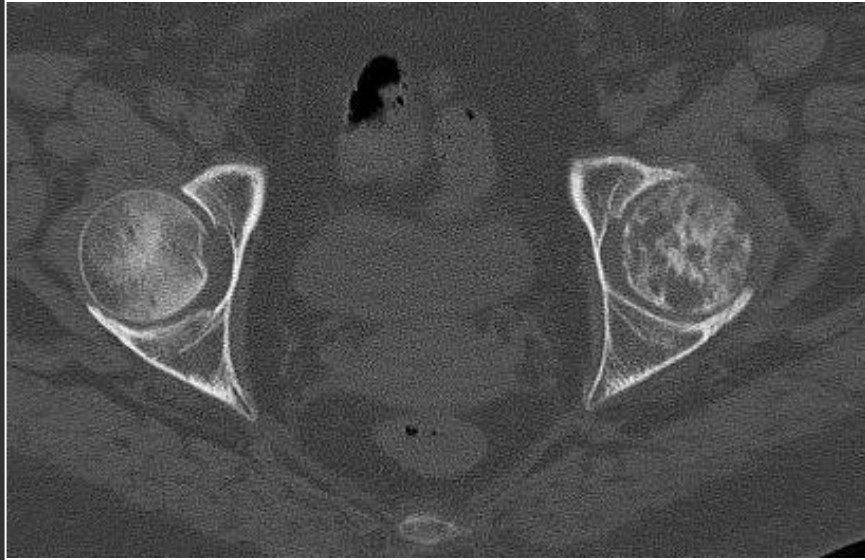
X-Ray and MRI – Radiolucent lesion in distal femur that extends to articular surface. Although radiographic appearance is compatible with an aggressive (there is cortical rupture and soft tissue mass) giant cell tumor, advanced age of patient and history of renal cell carcinoma argues otherwise. Results of pathologic examination confirmed solitary epiphyseal metastasis from a primary kidney tumor.

OSSEOUS METASTASIS – CASE 2 - Woman, 61 years



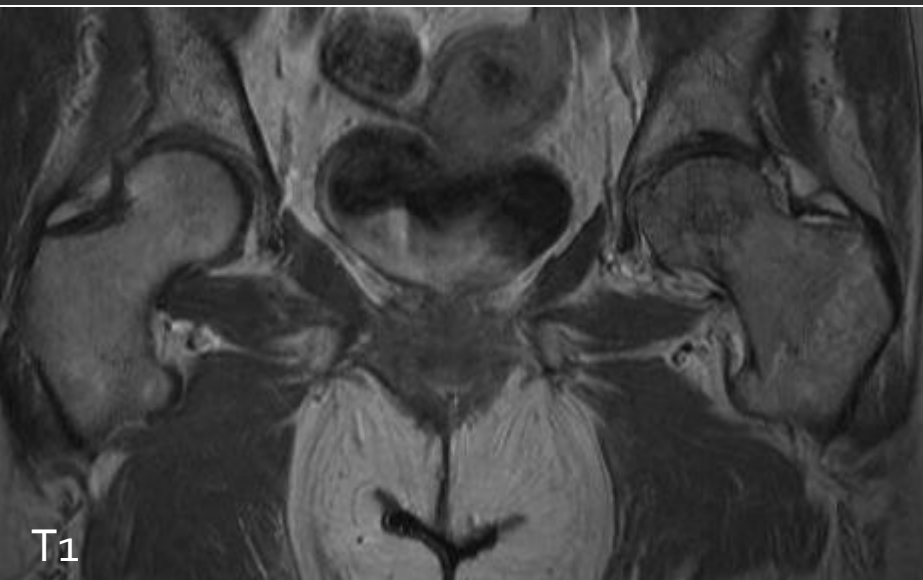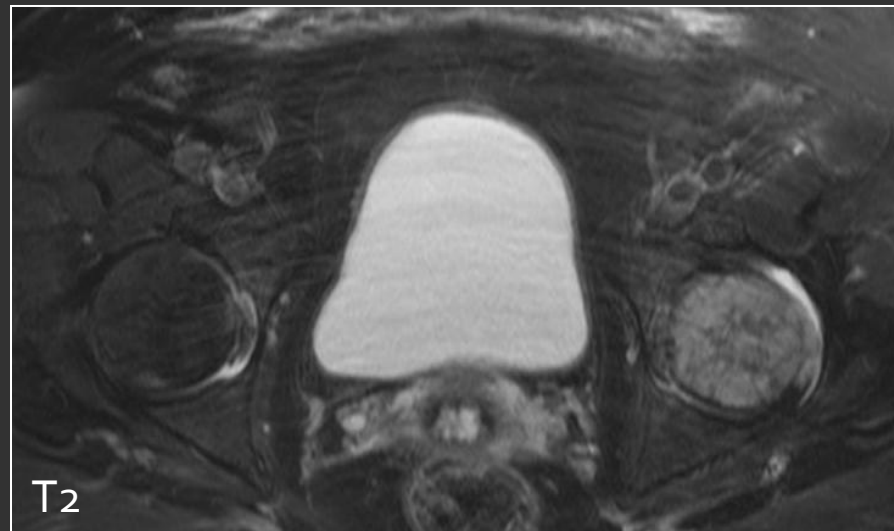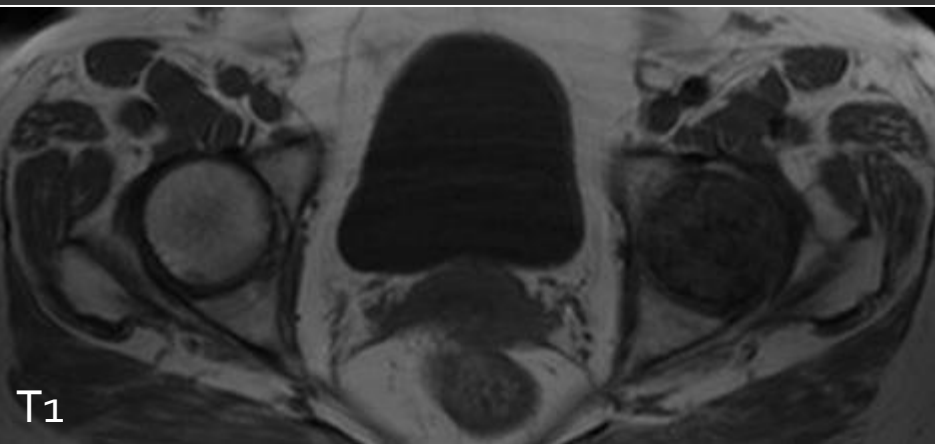
X-Ray – This patient with lung carcinoma had morphologic and structural changes of left head and neck of femur, with multiple and confluent faintly seen lytic lesions. This was suspicious for osseous metastasis.

OSSEOUS METASTASIS – CASE 2 - Woman, 61 years



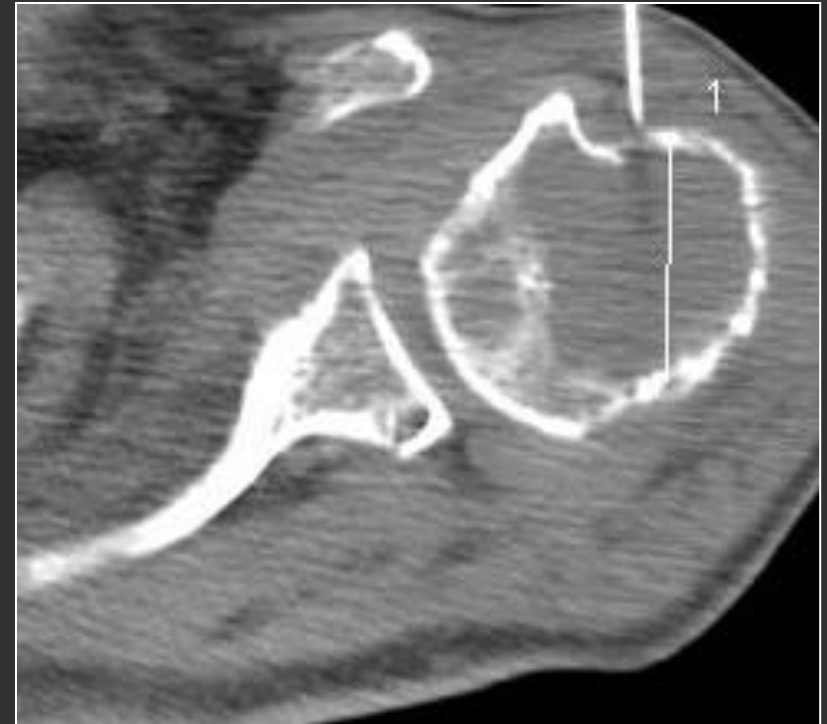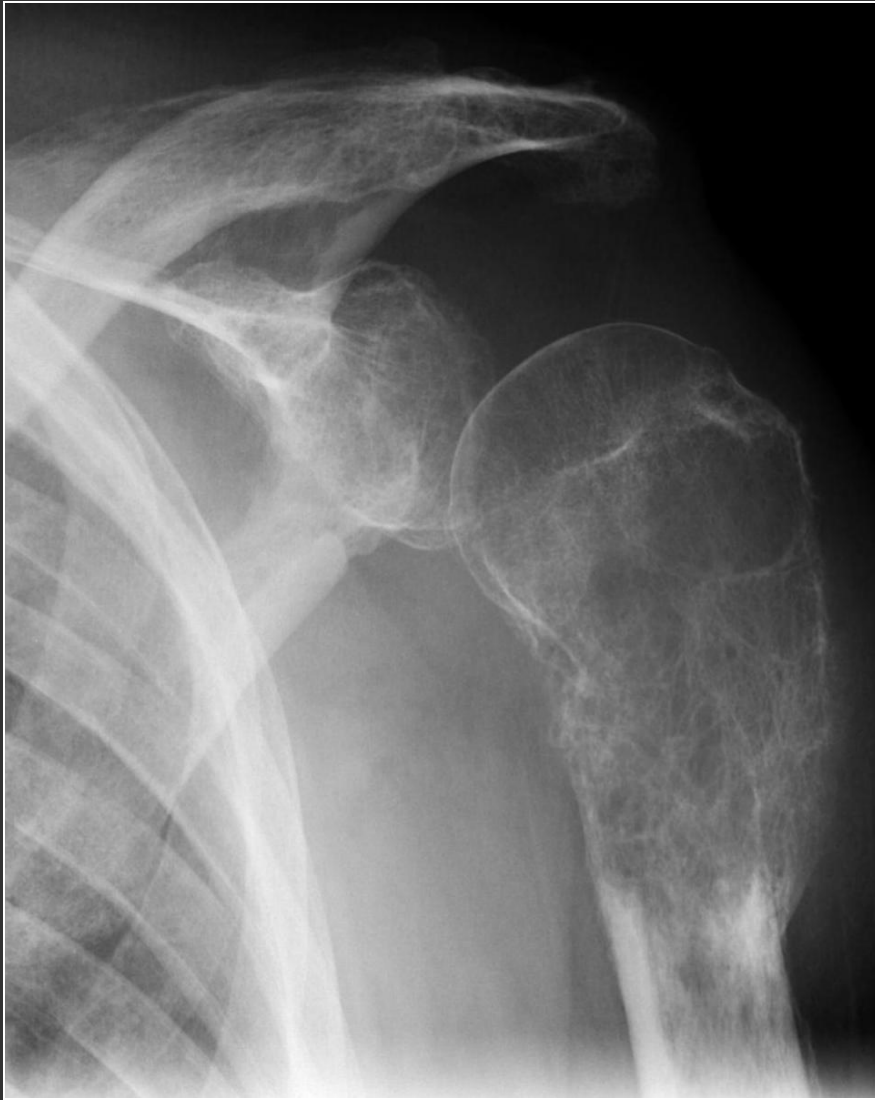CT confirms that there are multiple and confluent lytic lesions of femoral head and neck. The diagnosis of metastases is straightforward if numerous lesions are noted throughout the skeleton and the patient has a primary tumor like this case.

OSSEOUS METASTASIS – CASE 2 - Woman, 61 years



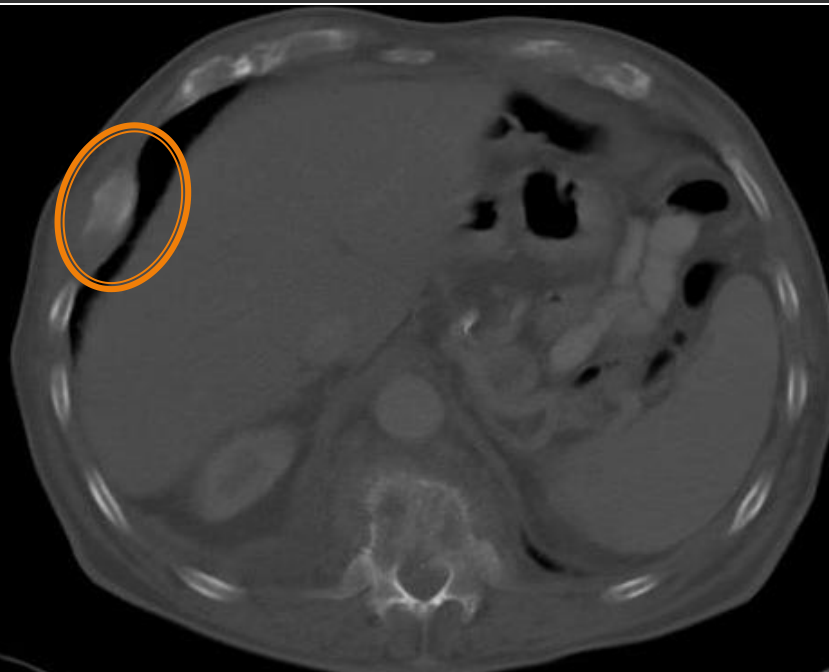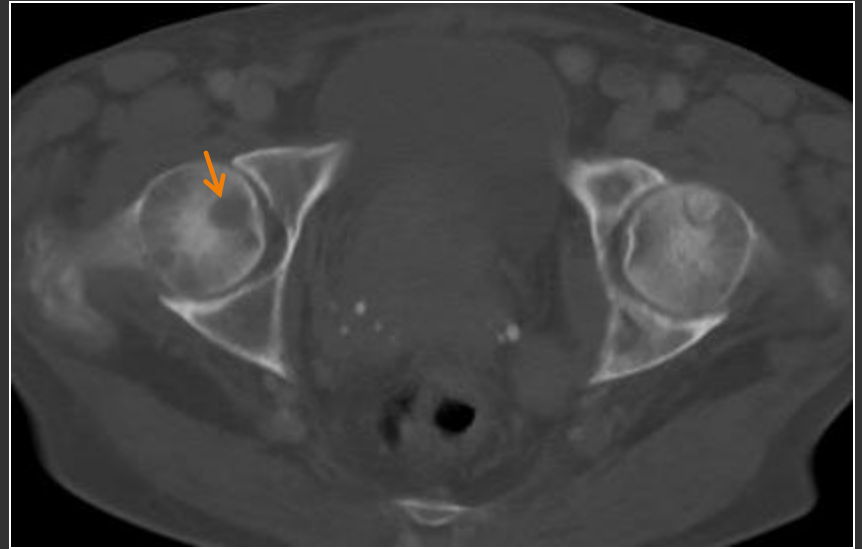
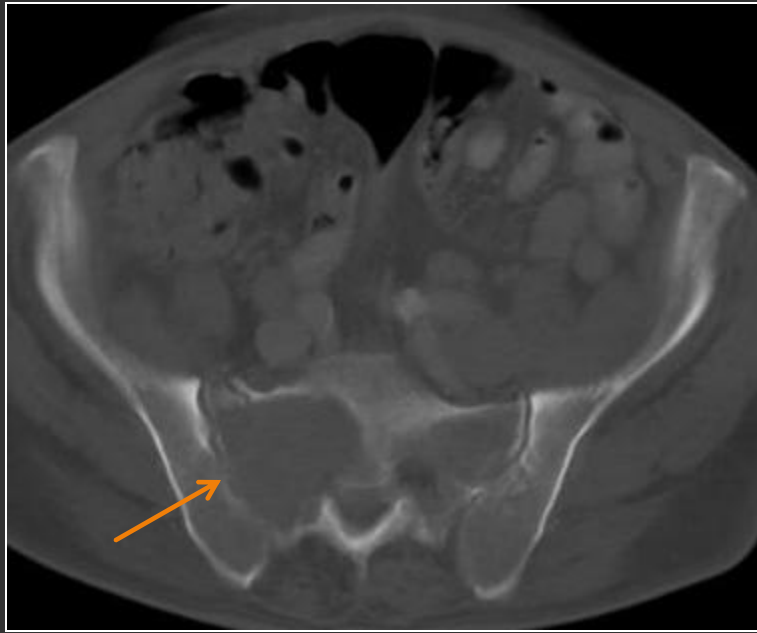MRI – The lesion is heterogeneous, with low signal on T1 and high signal on T2.

OSSEOUS METASTASIS – CASE 3 - Man, 71 years



X-Ray and CT – This is another patient with metastasis of renal cell carcinoma located in metaphysis and epiphysis of left humerus. Typically an expansile lytic metastasis should be either renal (like this case) or thyroid in origin.

OSSEOUS METASTASIS – CASE 3 - Man, 71 years



CT - This patient had other metastasis throughout the body: sacrum (the largest one), right femoral head, ribs and spine (not shown).

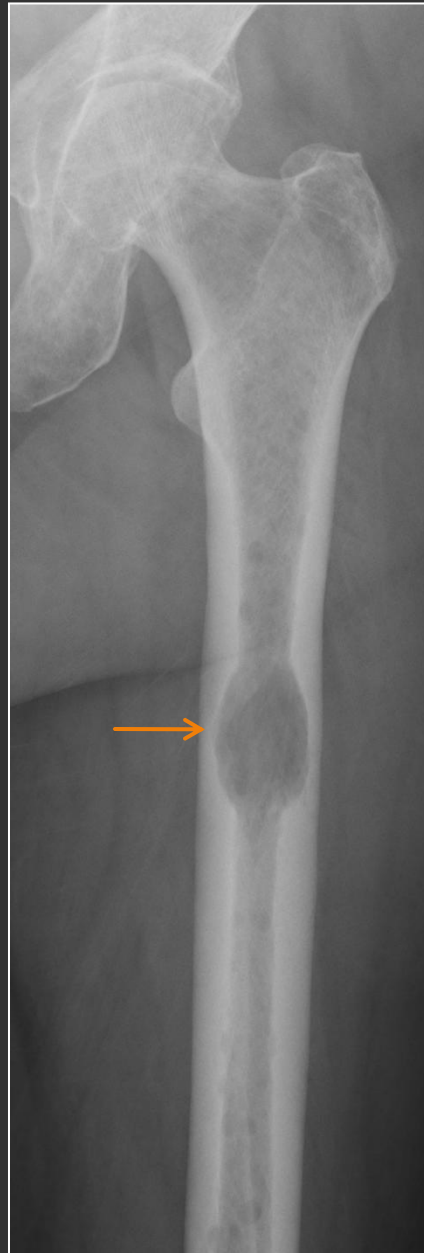
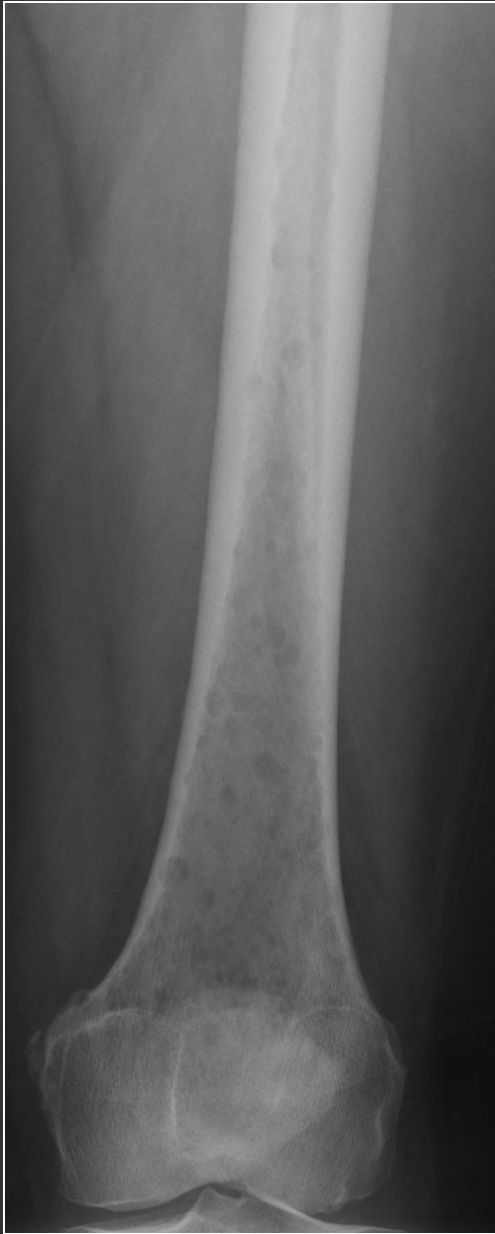MULTIPLE MYELOMA

- Most common appearance: Multiple punched-out lytic lesions with a narrow zone of transition
- May present as diffuse osteopenia, without focal lytic lesion
- Occasionally presents as a focal lytic expansile lesion – plasmacytoma – usually have a relatively narrow zone of transition, without sclerotic margins and no matrix calcification
- Bone scanning and skeletal radiographic survey are complementary studies, as each misses a large number of myeloma lesions

MULTIPLE MYELOMA

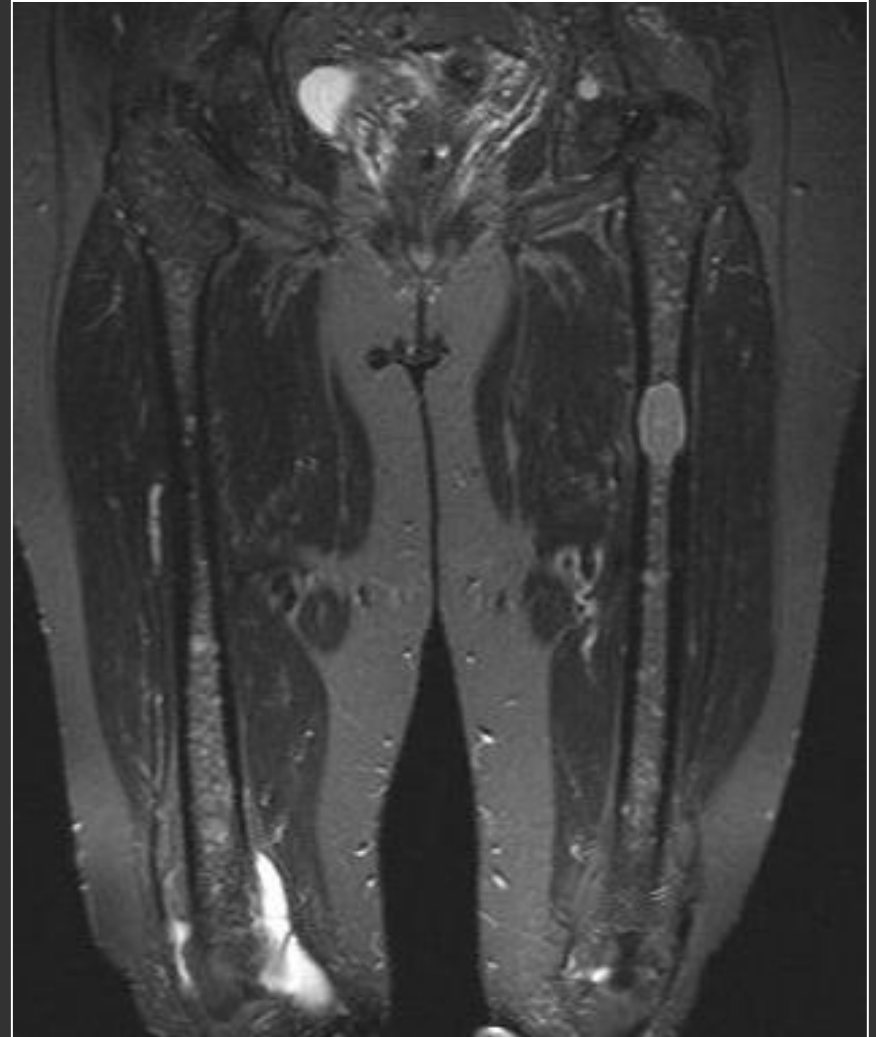
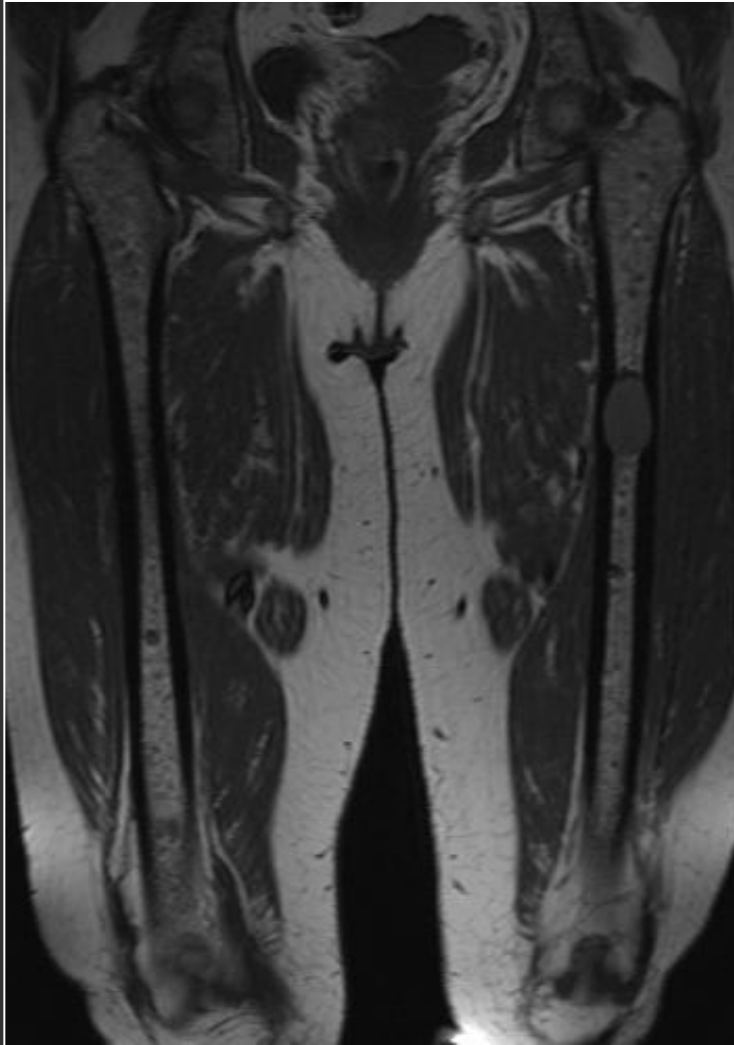
- The most common sites of occurrence reflect the distribution of red marrow in the skeleton – skull, vertebral bodies, pelvis, femur and humerus
- Like metastasis, generally myeloma should be considered only in a patient older than 40 years

MULTIPLE MYELOMA – CASE 1 - Man, 66 years



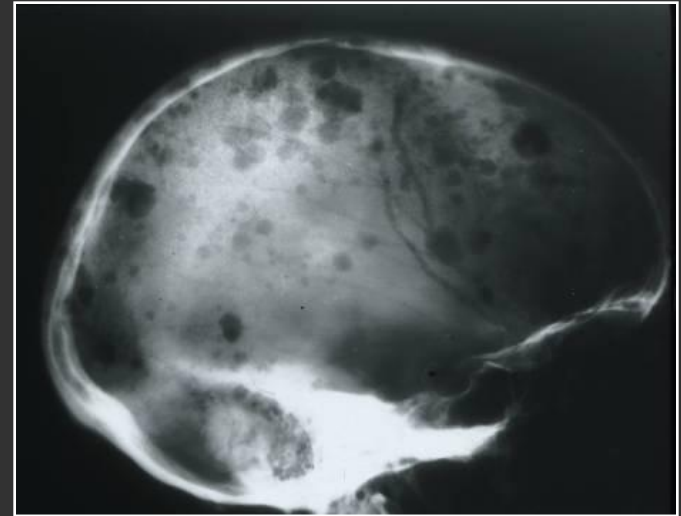
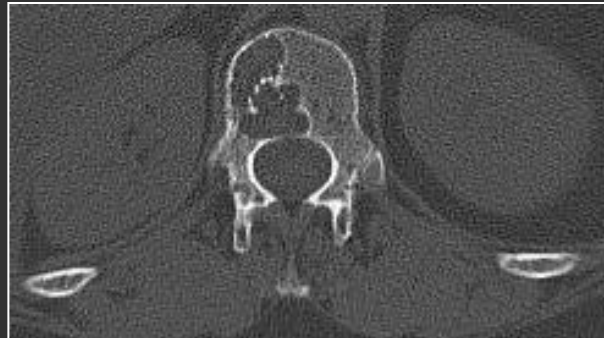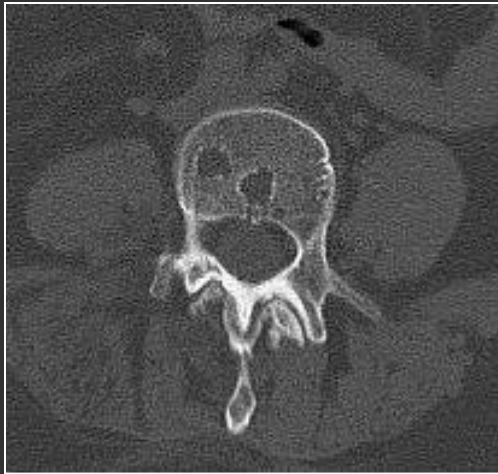
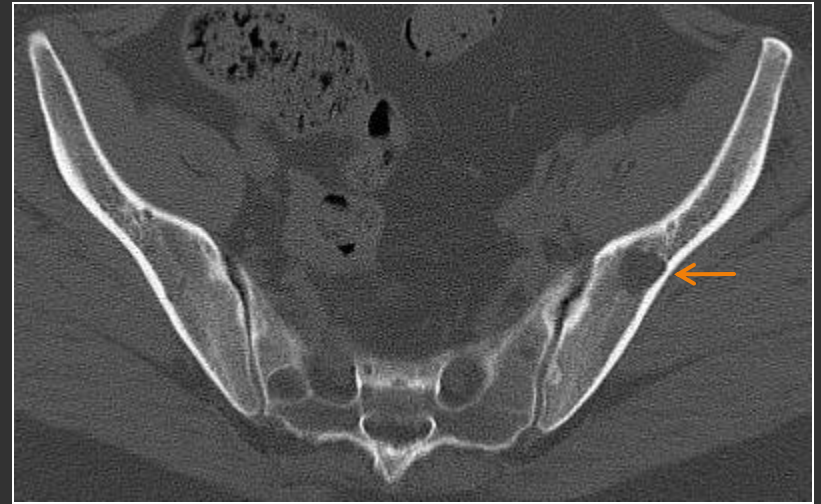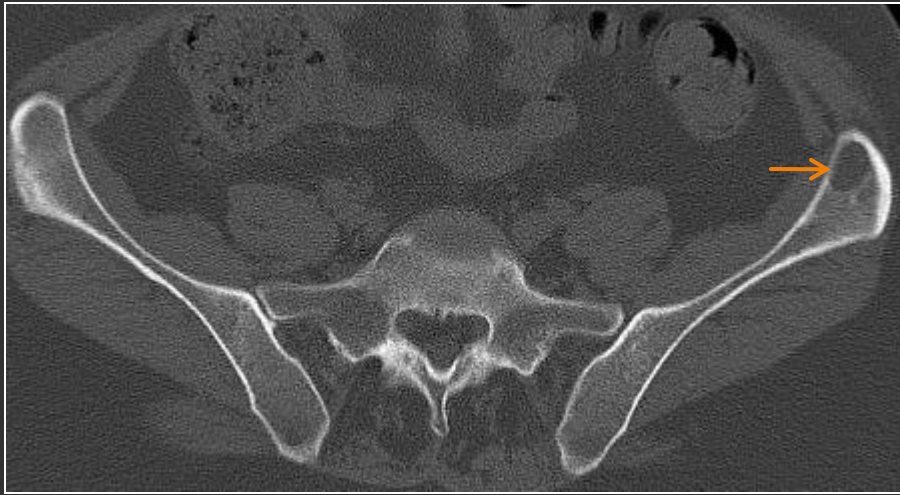X-Ray – A diffuse moth-eaten pattern is seen throughout the diaphysis, metaphysis and epiphysis of the femur, which is characteristic for myeloma. In the upper third of diaphysis there is a central well defined lytic lesion (*arrow*).

MULTIPLE MYELOMA – CASE 1 - Man, 66 years



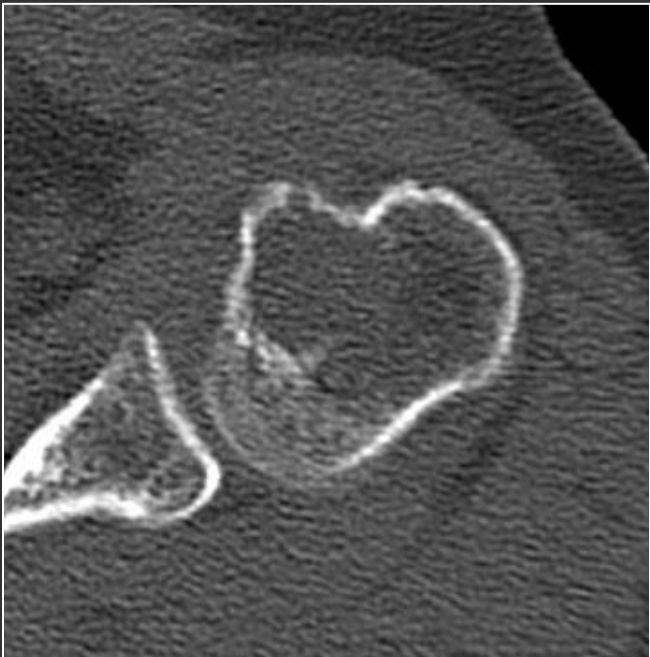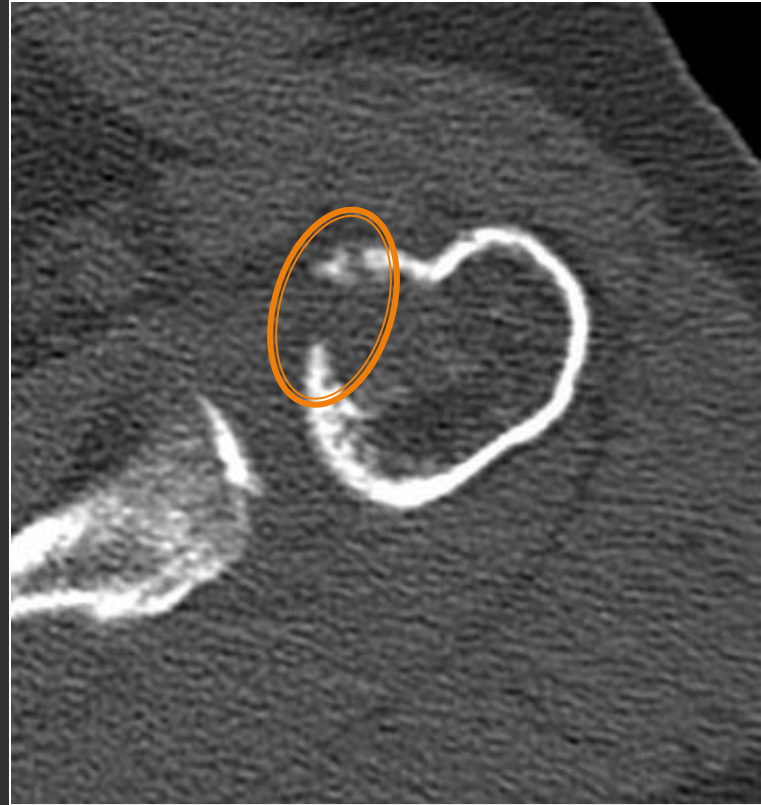
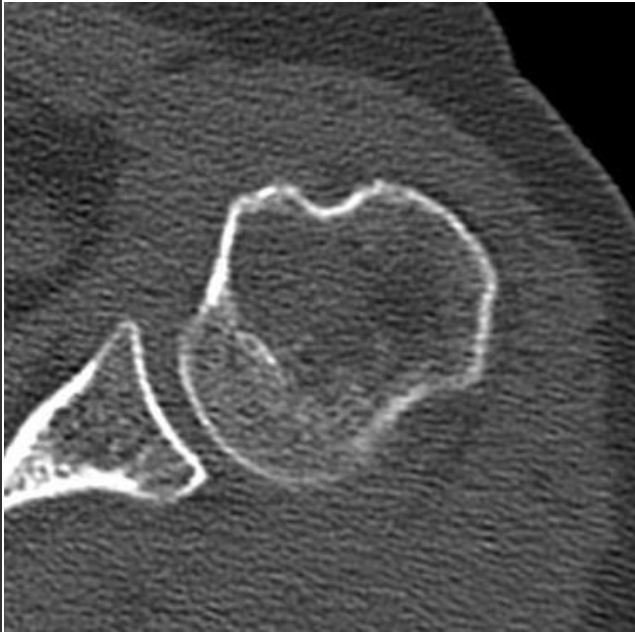
MRI – Multiple nodules throughout the femur, with low signal on T1 and high signal on T2.

MULTIPLE MYELOMA – CASE 2 - Woman, 46 years



CT and X-Ray - Multiple punched-out lytic lesions with a narrow zone of transition – skull, vertebral bodies and pelvis. These are the most common sites of occurrence and reflect the distribution of red marrow in the skeleton.

PLASMACYTOMA – CASE 3 - Woman, 53 years



CT - Focal lytic expansile lesion of humerus' epiphysis. There is evident cortical rupture (*circle*), but no periosteal reaction and no associated soft tissue mass. There were no lesions in the remaining skeleton and biopsy showed plasmacytoma. Remember, in patients with > 40 years, we cannot exclude metastases and multiple myeloma/plasmacytoma from the differential diagnosis of a lytic epiphyseal lesion.

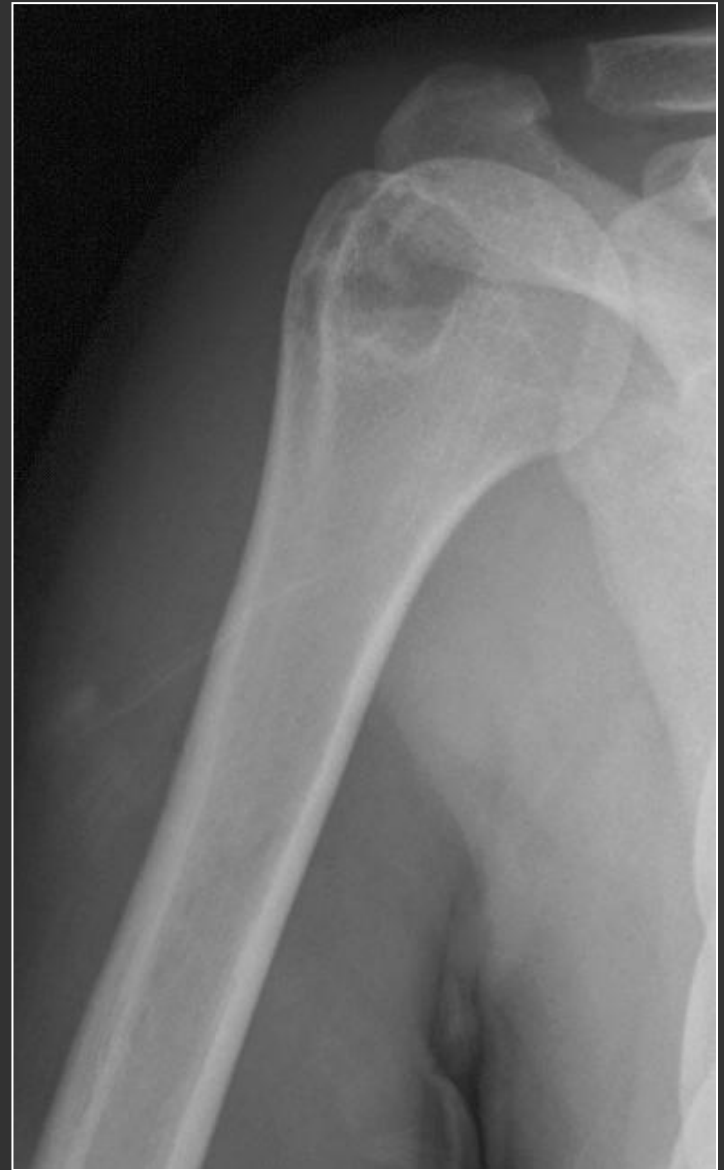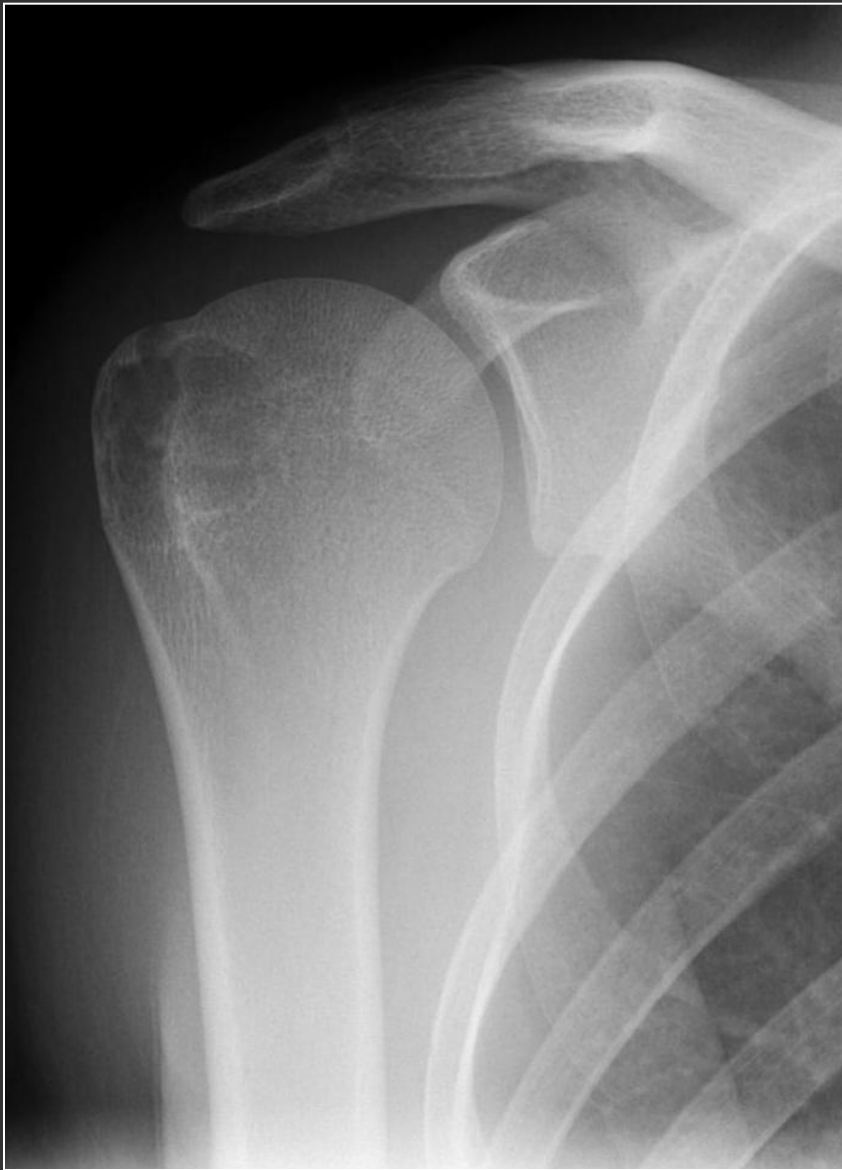ANEURYSMAL BONE CYST

- Expansile (often extremely), lytic, narrow zone of transition, eccentric, no tumor matrix
- Thin, intact shell of expanded overlying bone.
- Generally under 30 years of age
- CT and MRI demonstrate fluid-fluid levels in most cases
- Occasionally it is rapidly progressive, simulating a more aggressive lesion

ANEURYSMAL BONE CYST

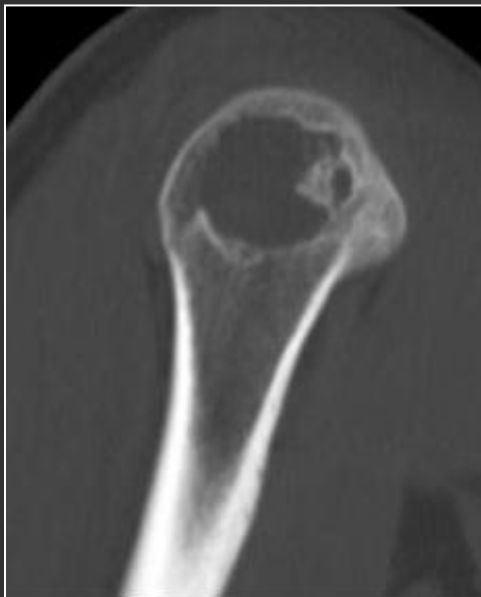
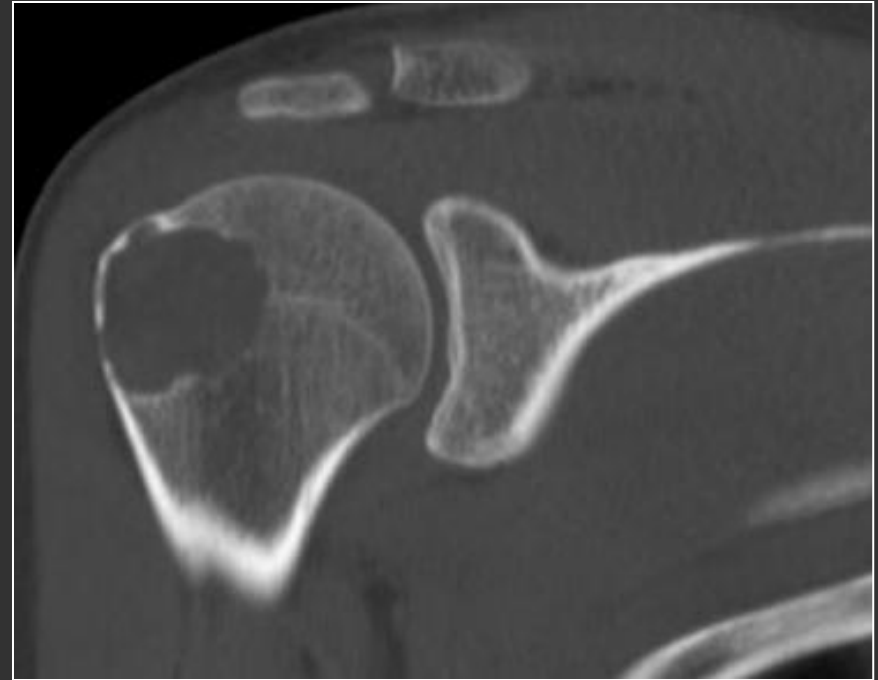
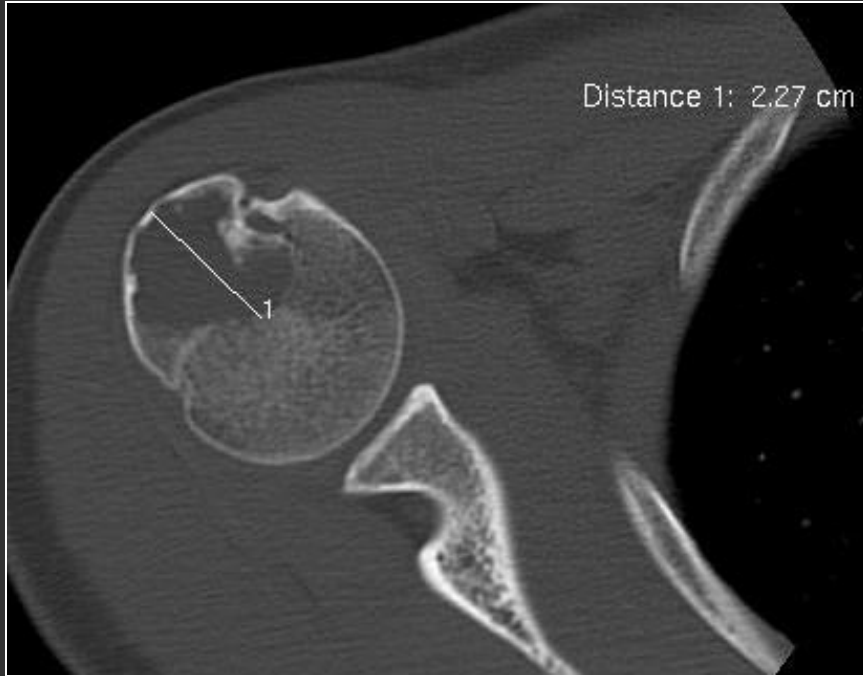
- May be post-traumatic (often cortically based) or secondary within a pre-existing tumor – look for a solid enhancing component that might represent the primary tumor
- Monostotic and usually occurs in the metaphyses or metadiaphysis of long bones
- Occasionally can occur in the epiphyses, but there is no location in which they should be given more weight in the differential

SECONDARY ANEURYSMAL BONE CYST - CASE 1 – Woman 22 years



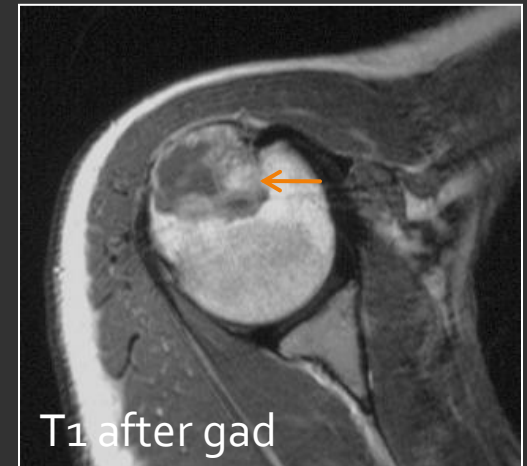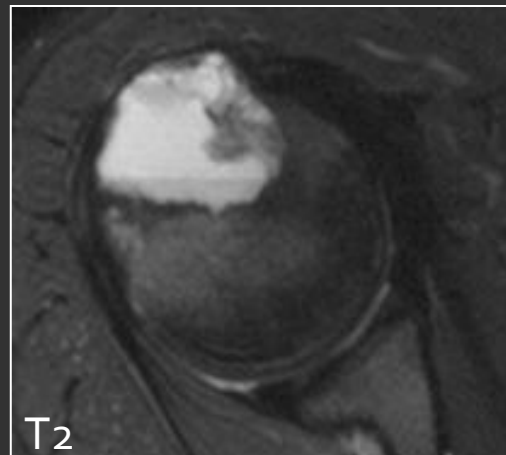
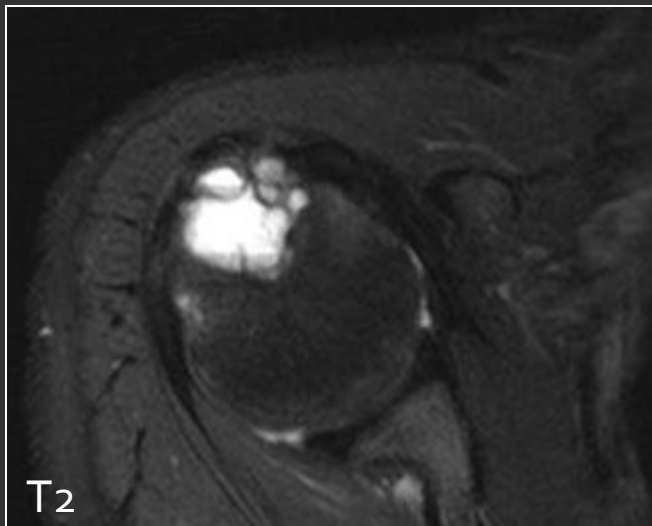
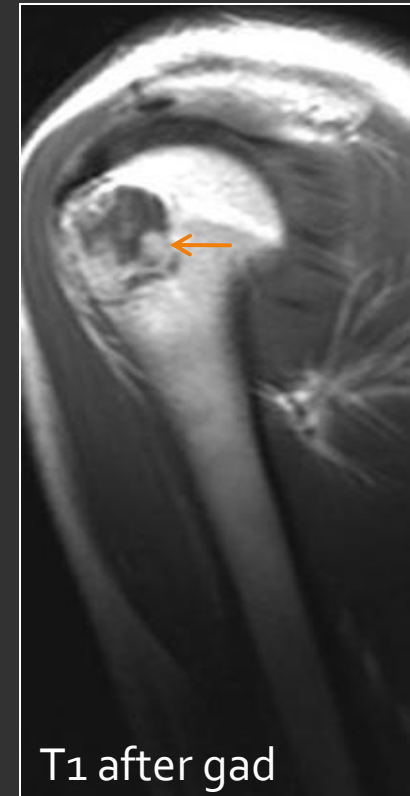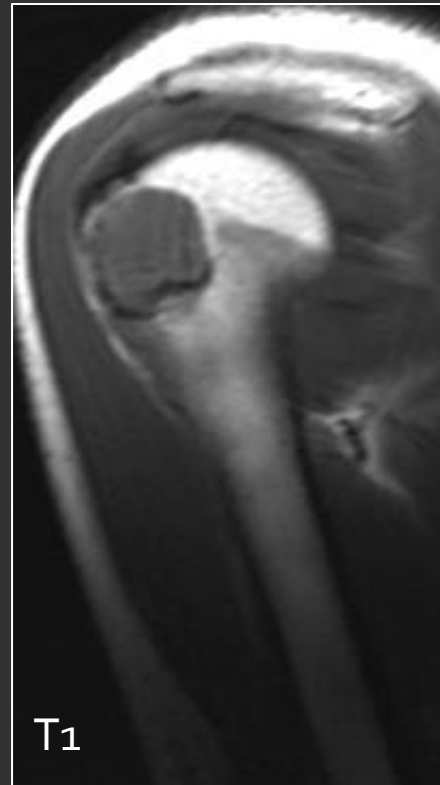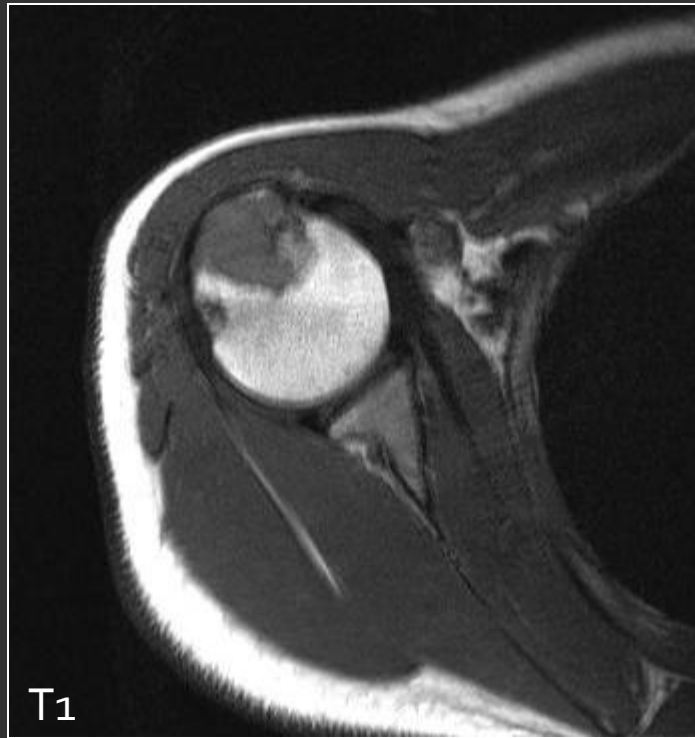X-Ray – Slightly expansile lytic lesion of metaphysis and epiphysis of right humerus. At first glance one might consider this typical for a giant cell tumor. However, note the sclerotic margins, that the lesion does not abut the articular surface and it is eccentric.

SECONDARY ANEURYSMAL BONE CYST - CASE 1 – Woman 22 years

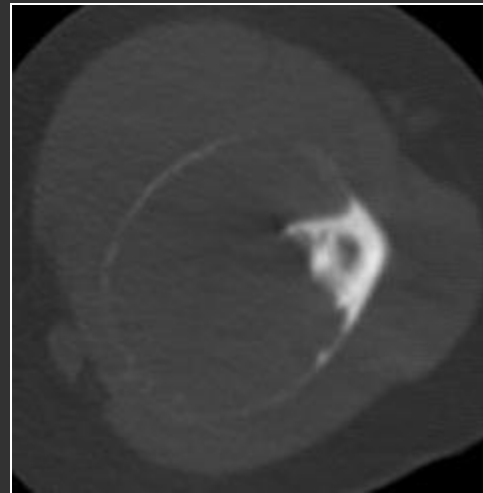
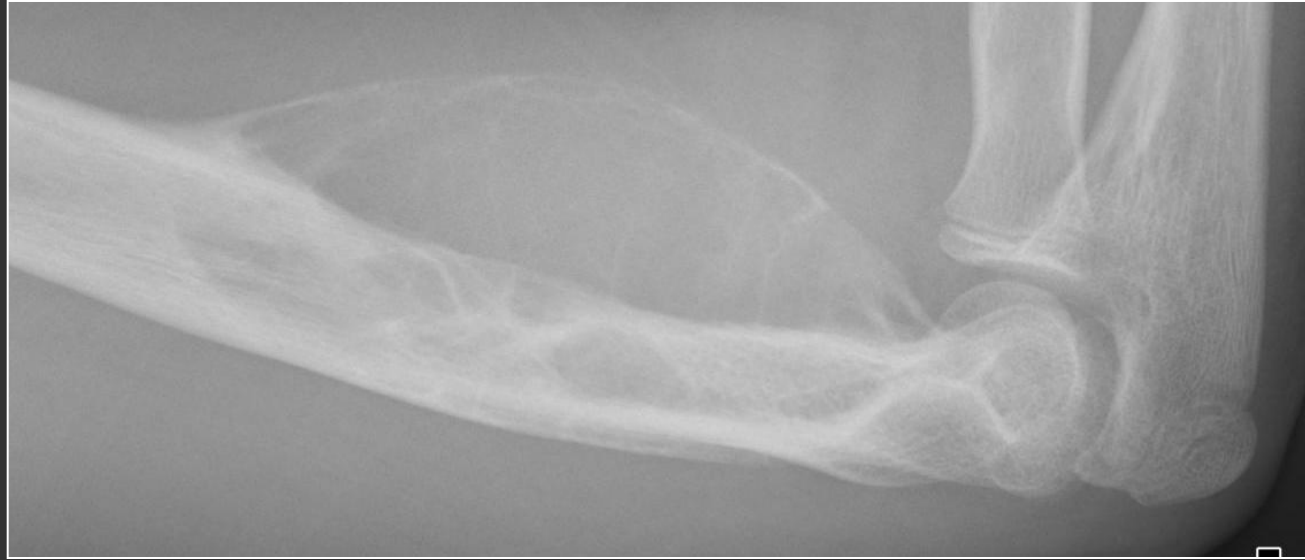
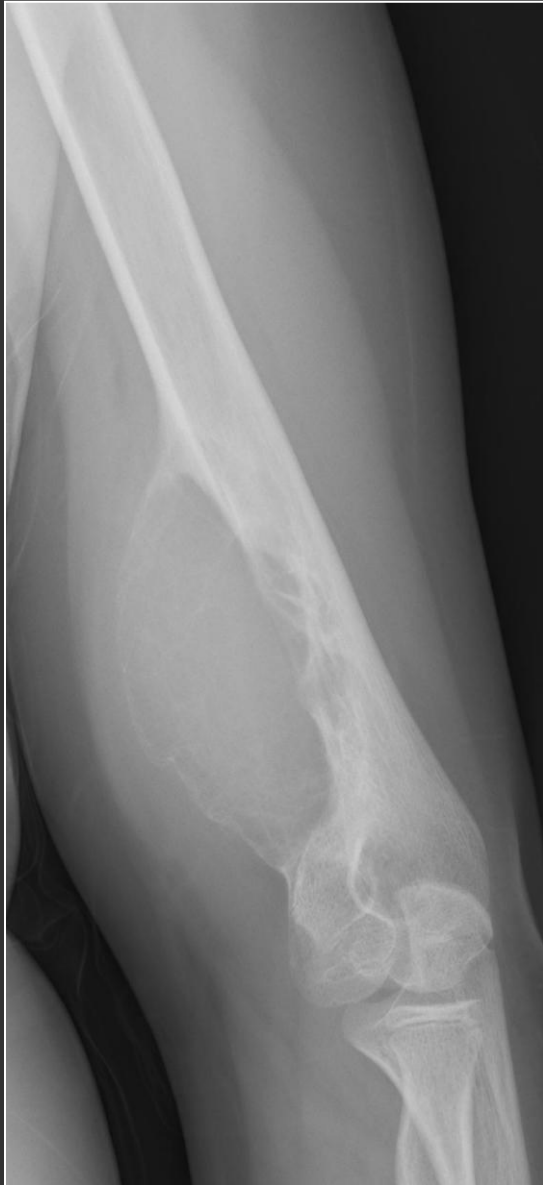

CT confirms that there is some cortical thinning, but no cortical rupture, no tumoral matrix calcification and no associated soft tissue masses.

SECONDARY ANEURYSMAL BONE CYST - CASE 1 – Woman 22 years

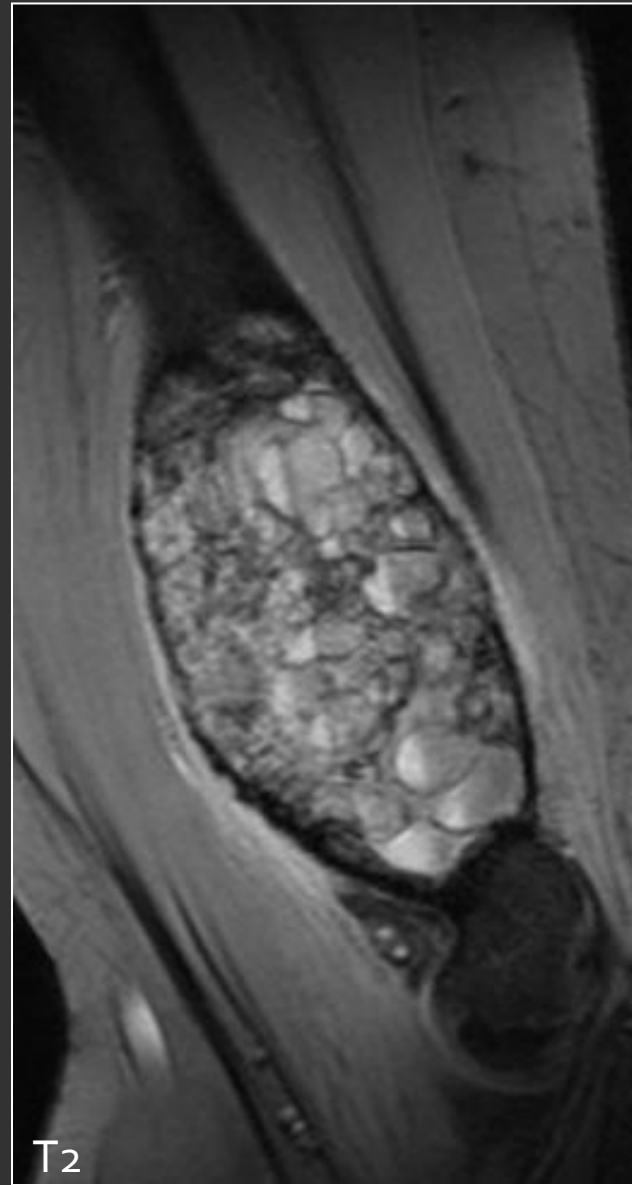
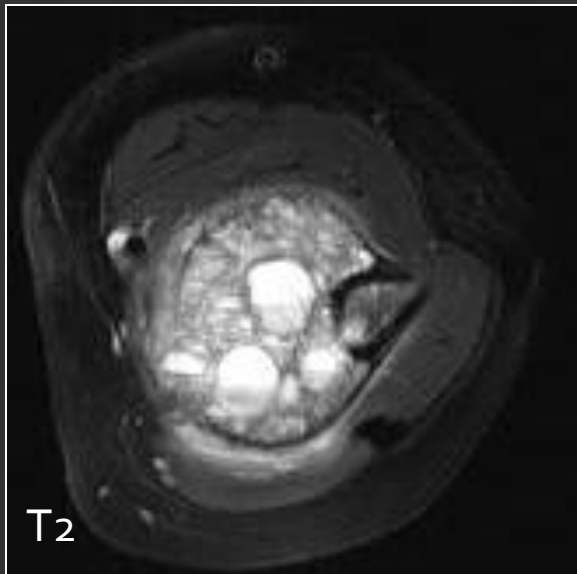
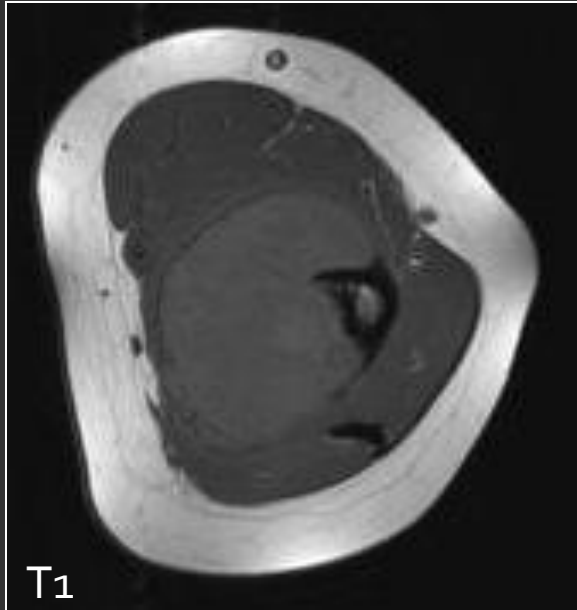


ANEURYSMAL BONE CYST - CASE 2 – Man 16 years

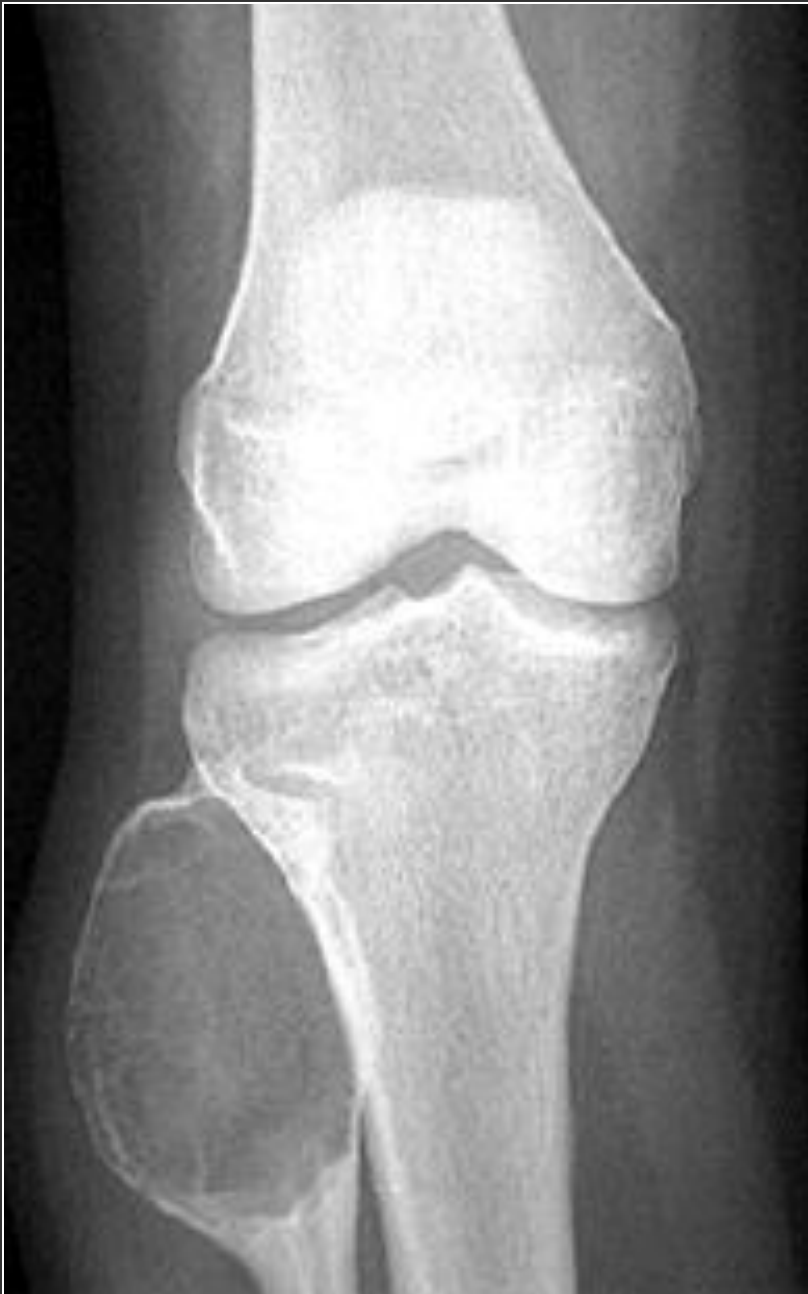

X-Ray and CT – This case is not an epiphyseal lesion. However this example demonstrates the typical appearance of aneurysmal bone cyst: an eccentric located metaphyseal and very expansile lesion; this is a large but nonaggressive lesion (no cortical rupture and no soft tissue mass associated).

ANEURYSMAL BONE CYST - CASE 2 – Man 16 years



MRI shows the typical bone expansion and multiple fluid levels (T2).

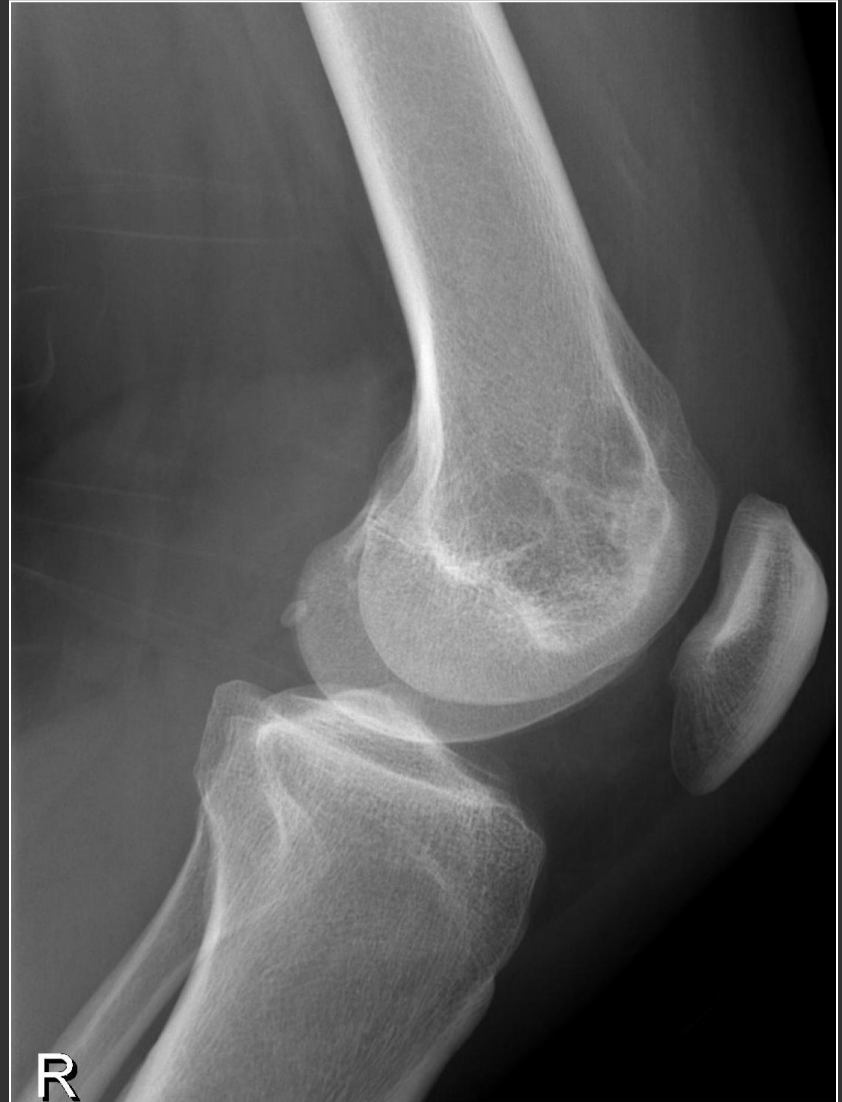
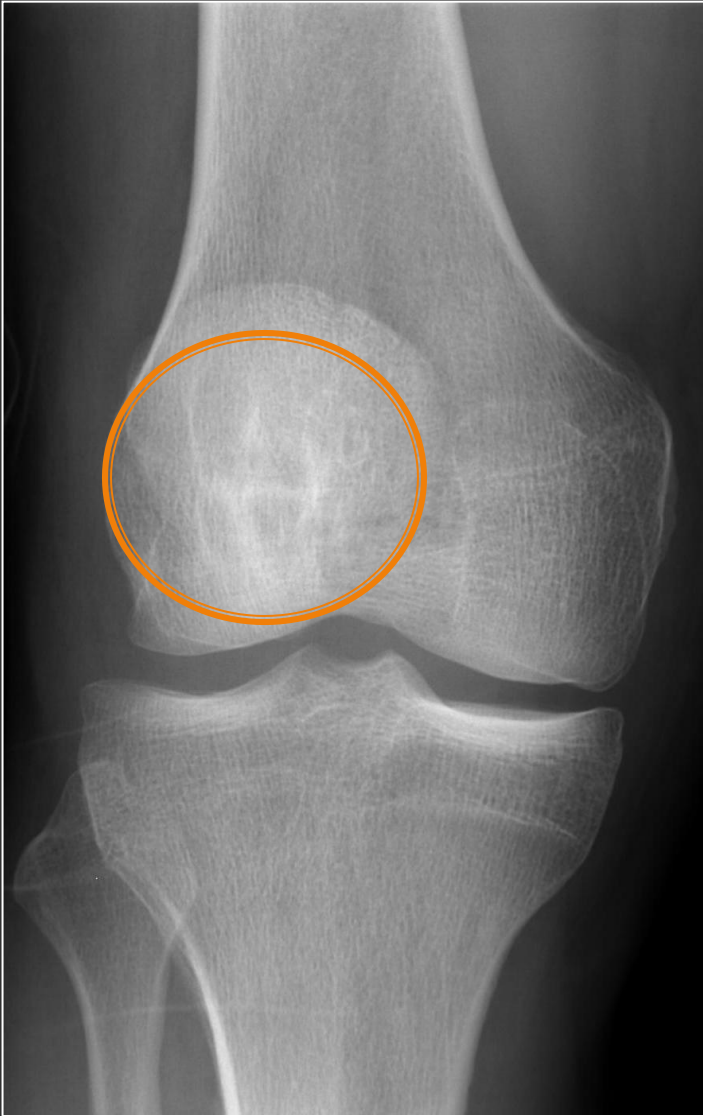
X – Ray – Very expansile (“aneurysmal”) lytic lesion of epiphysis and metaphysis of fibula. Repair in the thin, intact shell of expanded overlying bone, typical of aneurysmal bone cyst.

OSSEOUS LIPOMA

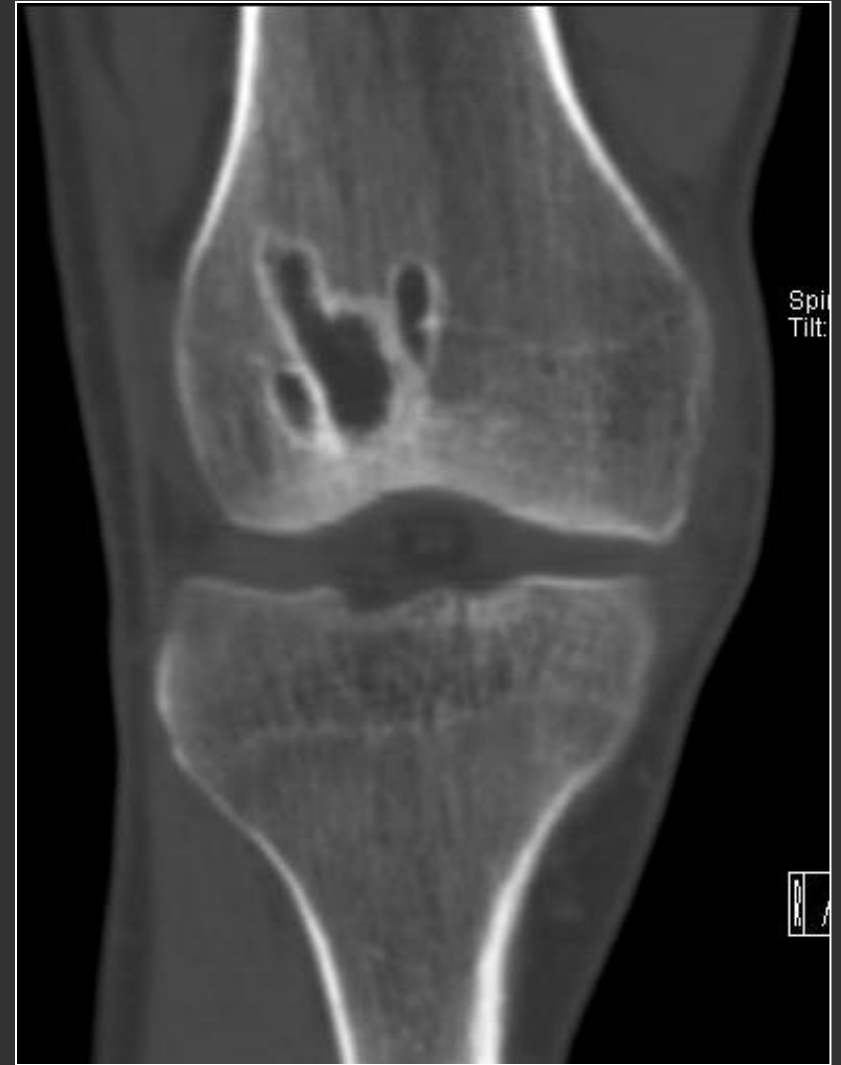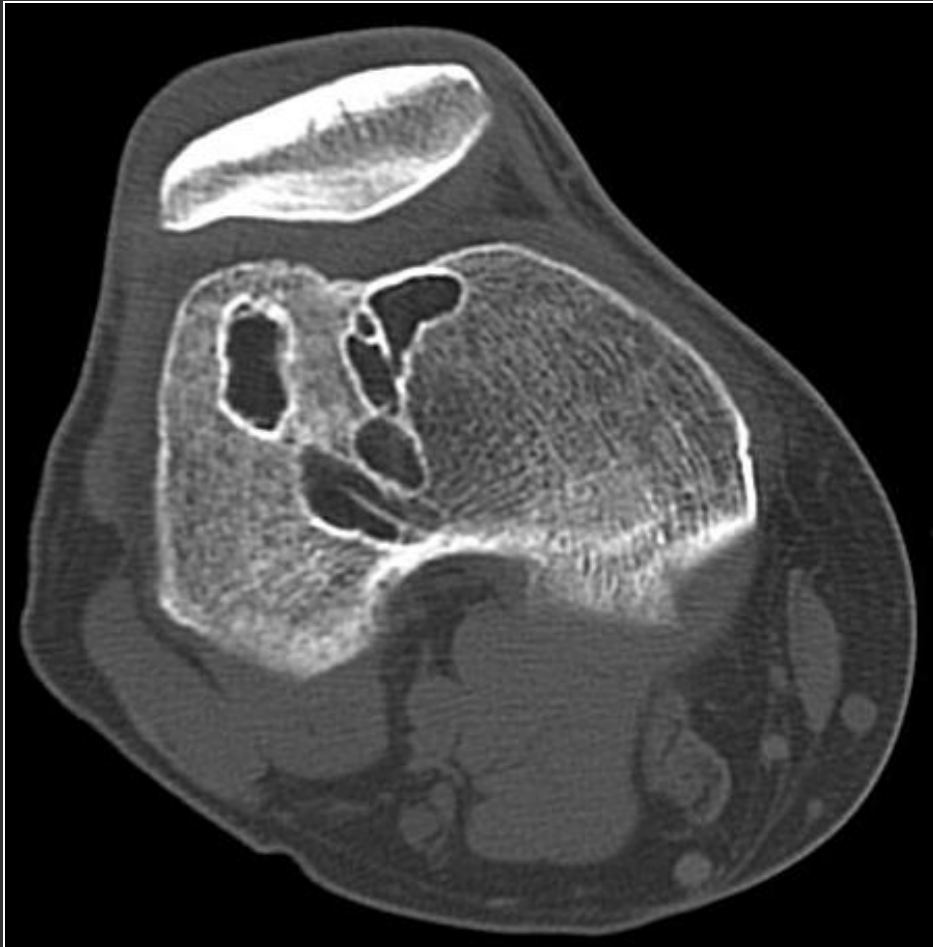- Rare fatty lesion of bone
- Lytic lesion with a geographic sclerotic margin and no matrix or host reaction
- Fat density on CT and fat signal intensity on MRI and may be distinguished by having a central nidus of dystrophic calcification
- Most often found in the metaphyses of long bones and the calcaneus, but can occur anywhere including epiphysis

OSSEOUS LIPOMA - Man, 45 years



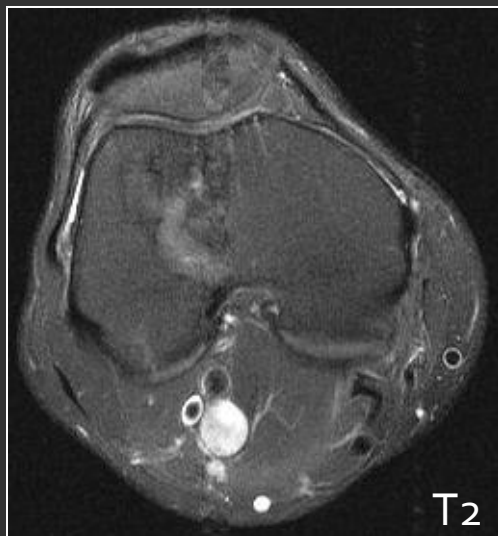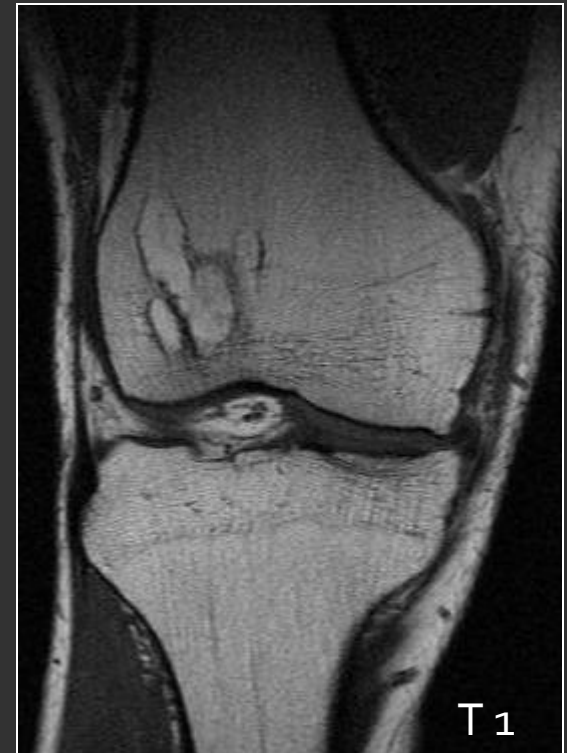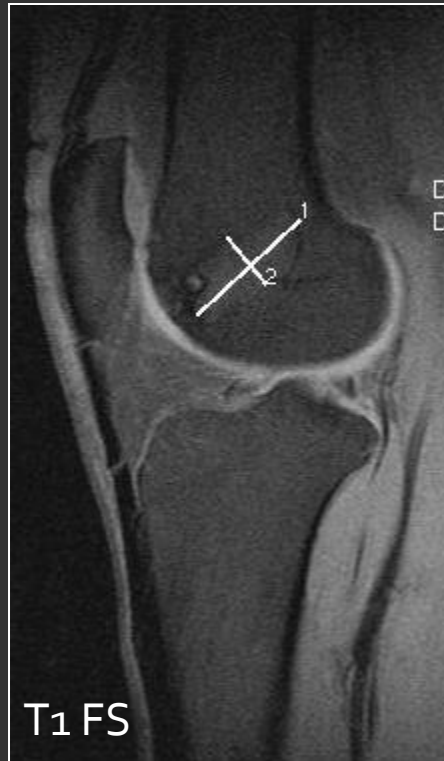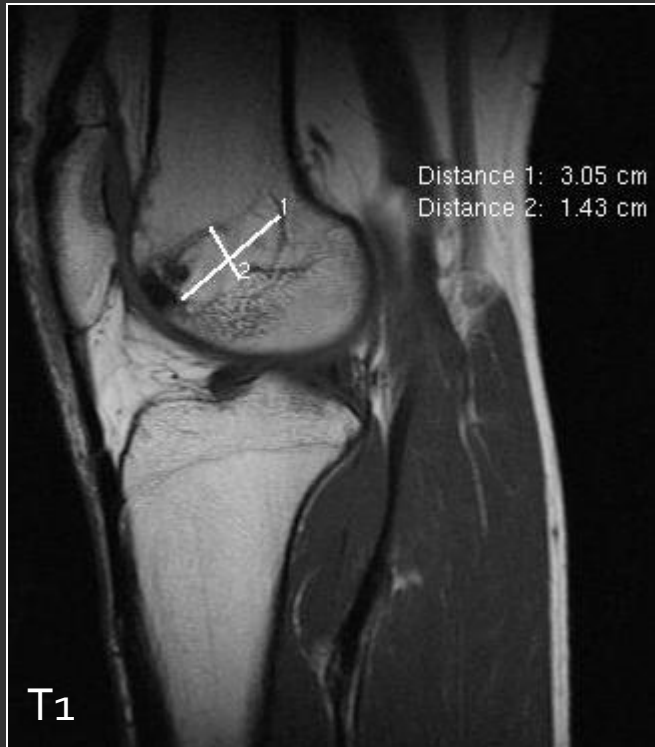X-Ray – “Multiloculated” lytic lesion located at lateral condyle of right femur. The margin of the lesion is geographic and sclerotic. There is no periosteal reaction neither soft tissue mass.

OSSEOUS LIPOMA - Man, 45 years



CT - The lesion is located at distal epiphysis of femur (predominantly lateral condyle); it has lobulated and sclerotic margins and it is of homogeneous fatty attenuation.

OSSEOUS LIPOMA - Man, 45 years



MRI - The tumor shows fat signal intensity on all sequences. Repair that the lesion loses signal intensity on T₁ with fat saturation (FS). This is a somewhat atypical case because lipomas are most often found in metaphysis.

OSTEOMYELITIS

- The radiologic spectrum of osteomyelitis is very large
- Periosteal reaction: without; linear periosteal reaction; thick periosteal reaction; laminated (“onion peel”); Codman’s triangle;...
- Bone destruction: Permeating bone lesion; Punched out bone; Moth-eaten; Geographic (Brodie’s abscess); Aggressive osteolysis; Well-defined osteolytic lesion with thick sclerotic border;...

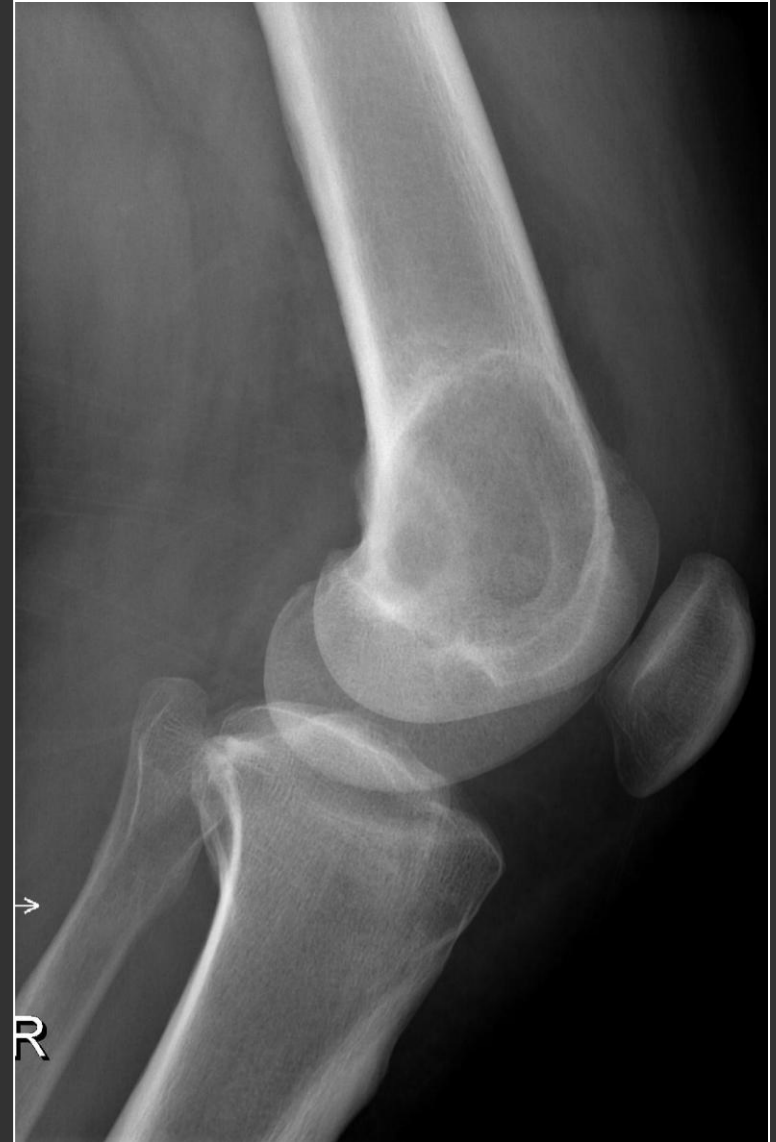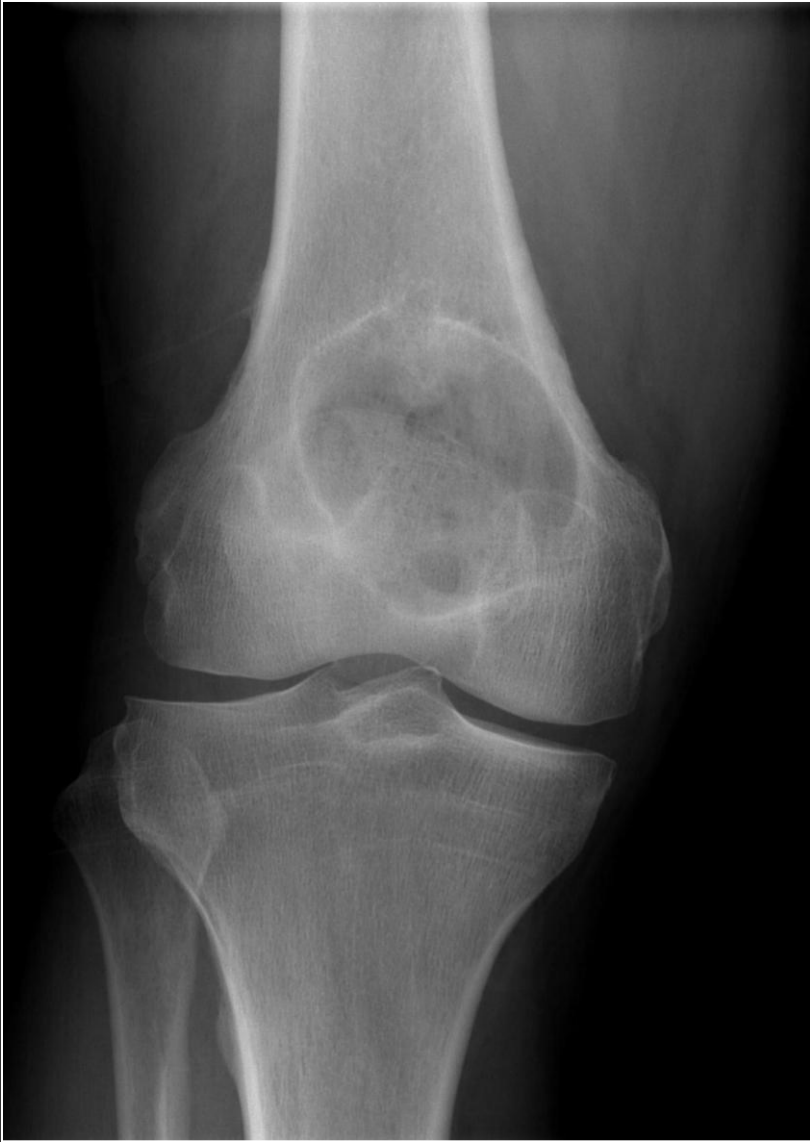OSTEOMYELITIS

- **Sequestrum**: Fragment of infected necrotic bone. Potential source of chronic infection.
- **Involucrum**: New bone formed around sequestrum
- **Sinus tract**: Soft tissue channel between bone and skin. Pus drains through it.
- **Cloaca**: Cortical and periosteal defect. Pus drains through it.
- **Abscess**: Pus-filled cavity lined with granulation tissue.
- **MRI for** abscess, sinus tract, cloaca, marrow edema and enhancement

OSTEOMYELITIS

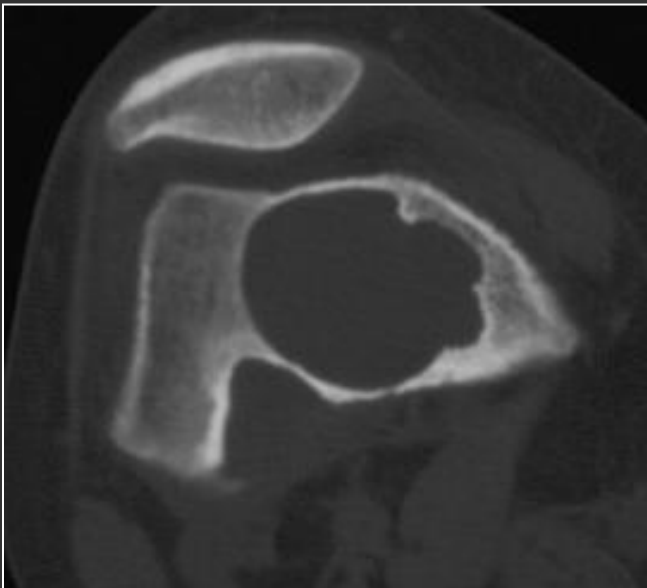
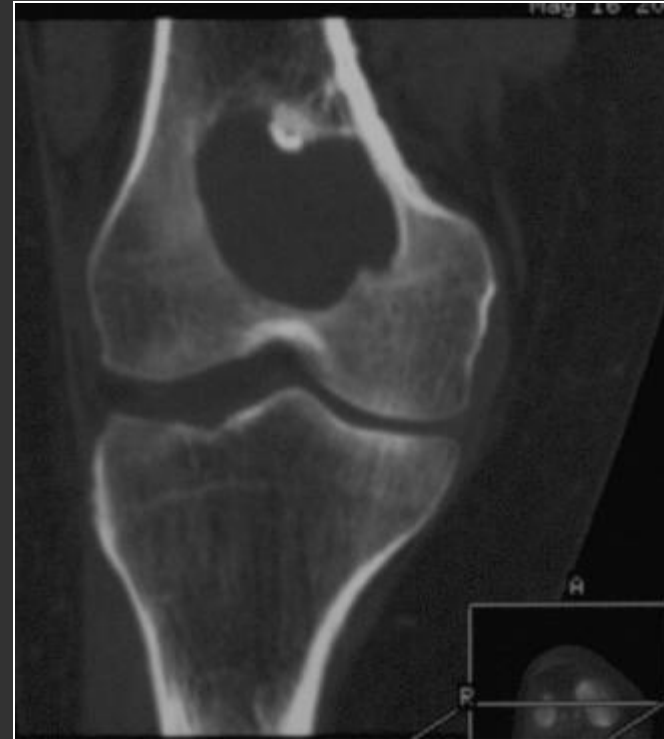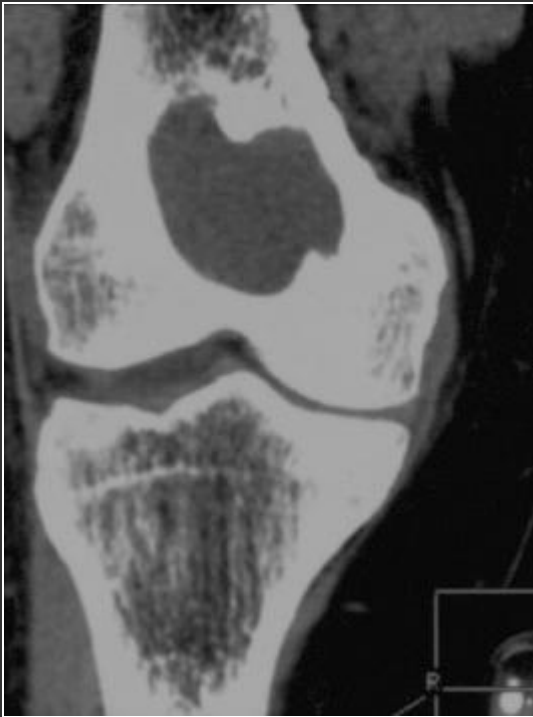- Can occur at any location and in a patient of any age
- When in the epiphysis (less common in children > 1 year, because blood vessels do not cross the physis), if the articular surface is abutted, invariably the adjacent joint will be involved and show either cartilage loss or an effusion, or both
- In conclusion, infection will be in almost every differential diagnosis of a lytic lesion (including epyphysis)

OSTEOMYELITIS (Brodie's abscess) - CASE 1 – Man 35 years



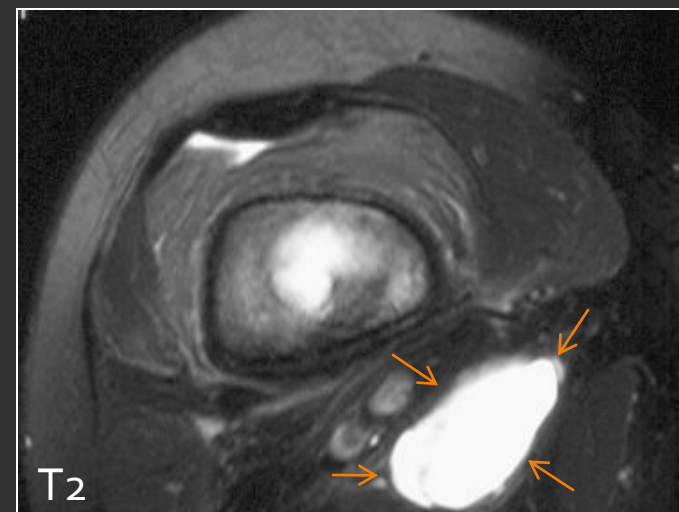
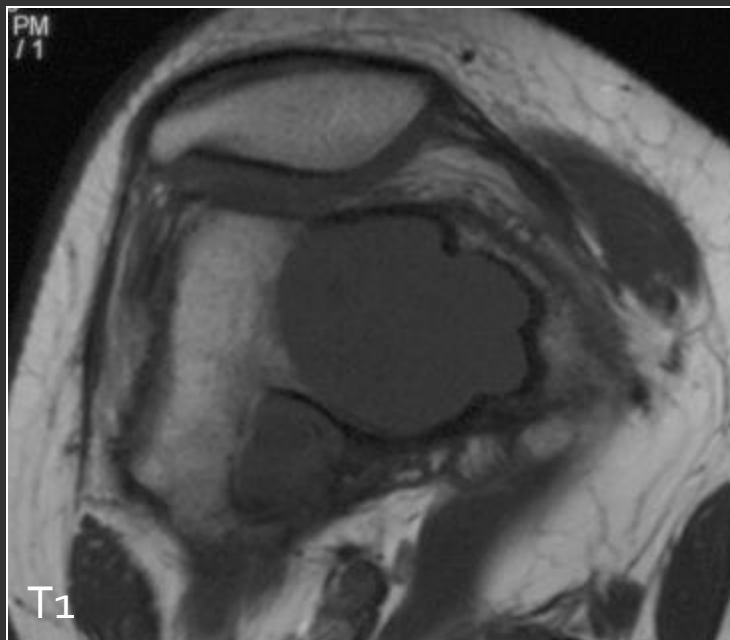
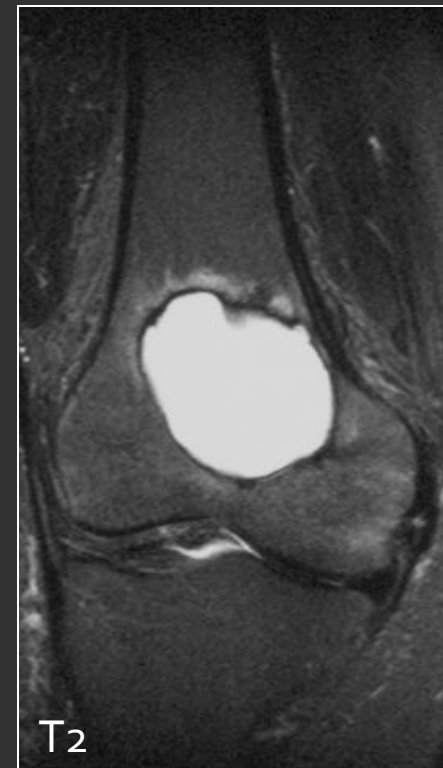
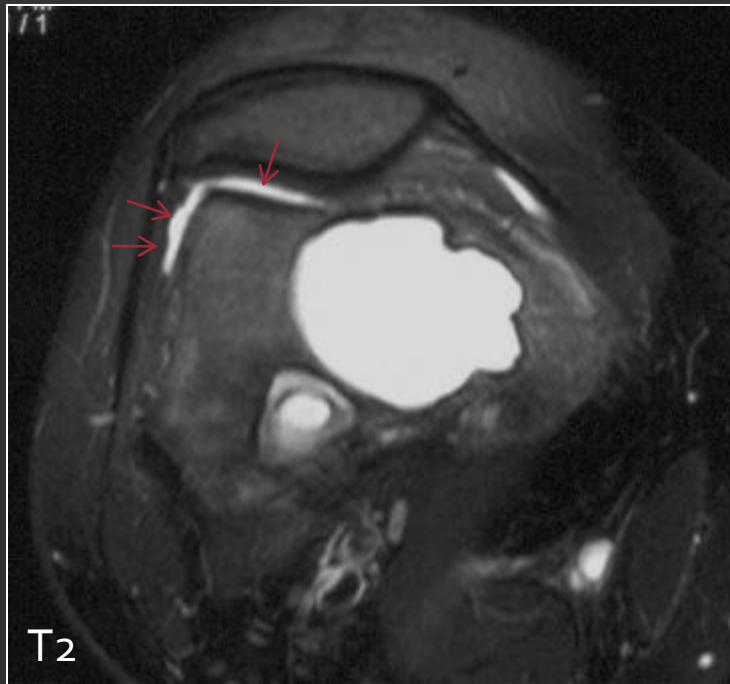
X-Ray – A focus of infection that was chronic in this patient is seen in the distal femur (epiphysis and metaphysis). This is the typical appearance for a Brodie's abscess – a geographic lytic lesion with a well-defined, often sclerotic margin.

OSTEOMYELITIS (Brodie's abscess) - CASE 1 – Man 35 years

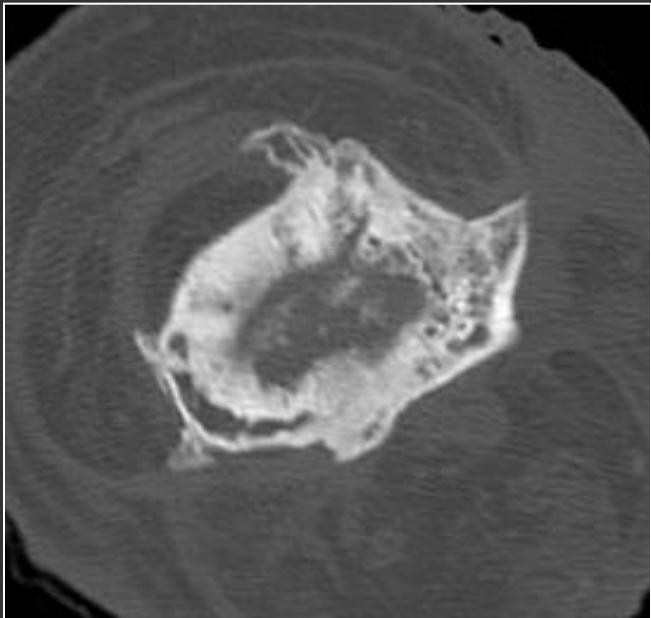
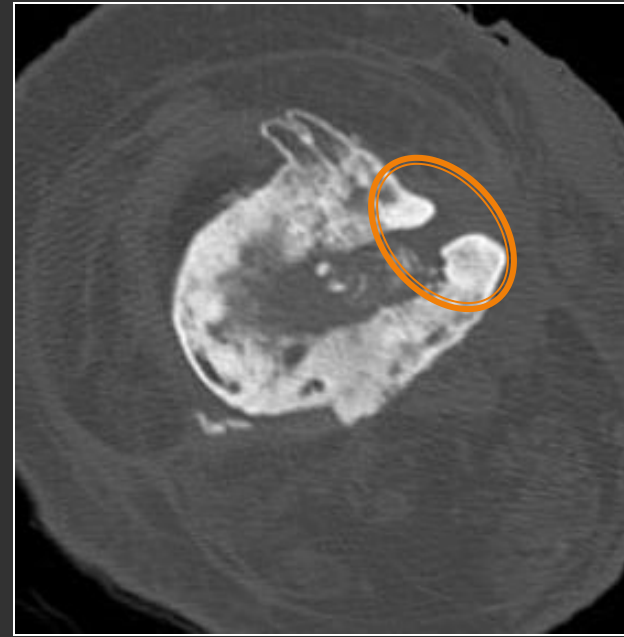
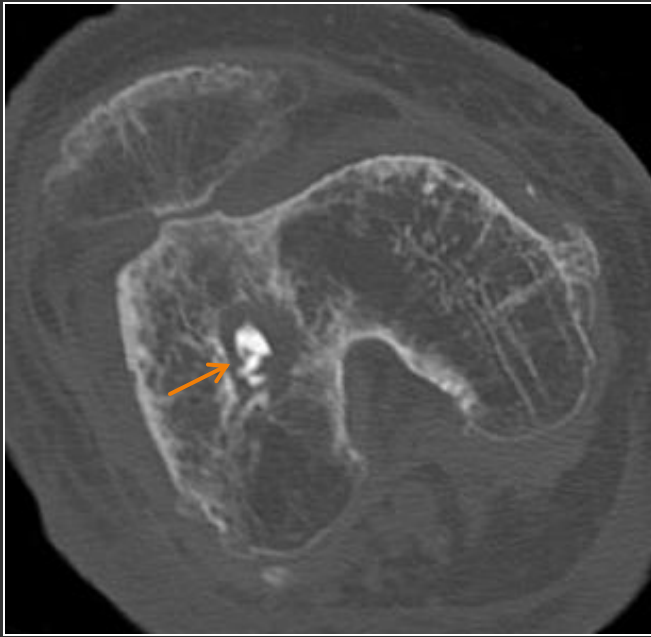


CT – The lesion has areas of water attenuation.

OSTEOMYELITIS (Brodie's abscess) - CASE 1 – Man 35 years

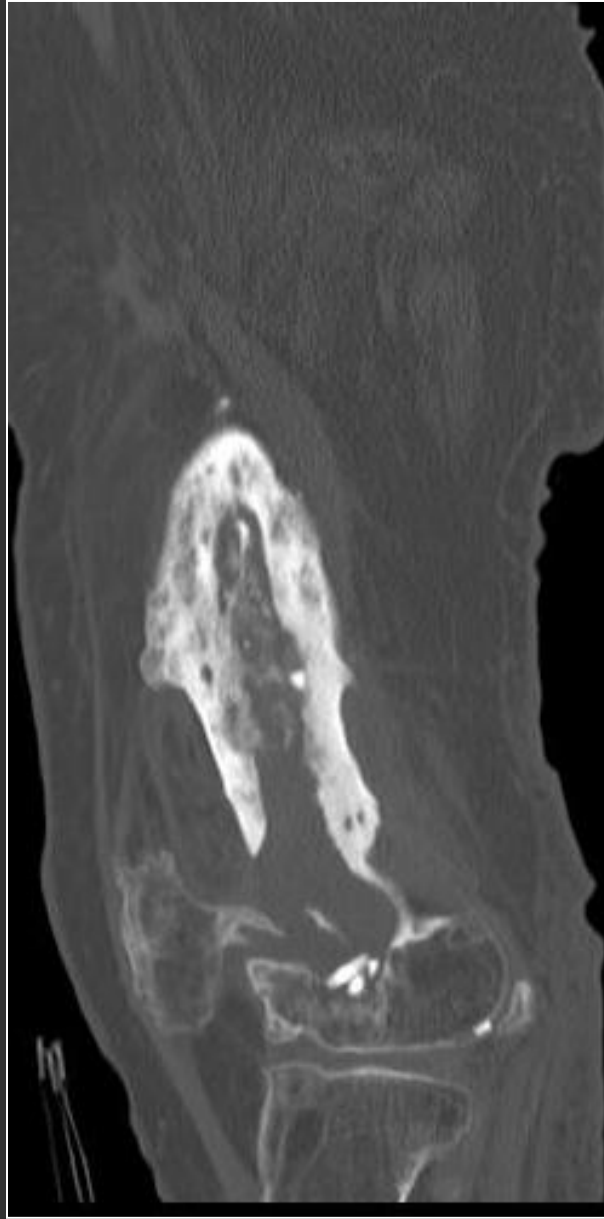
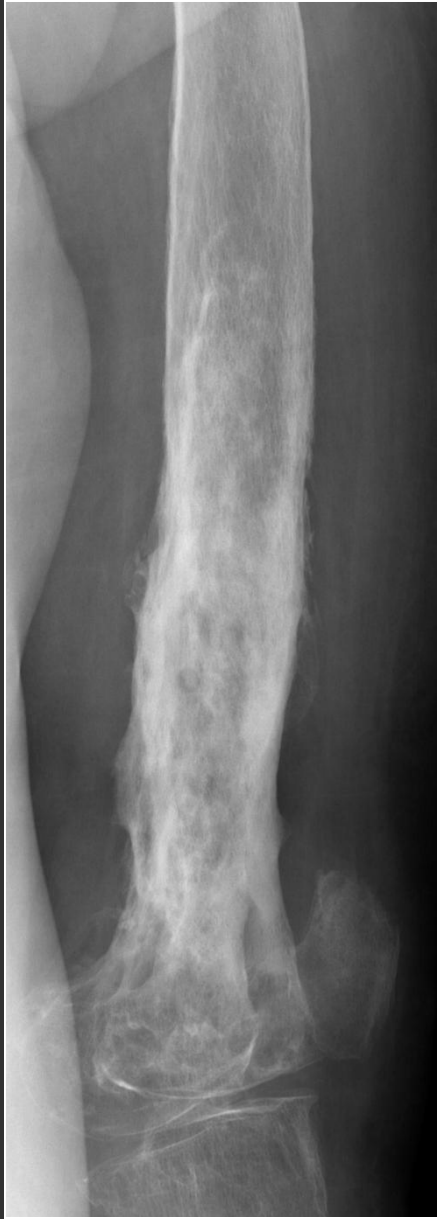

OSTEOMYELITIS - CASE 2 – Woman 77 years

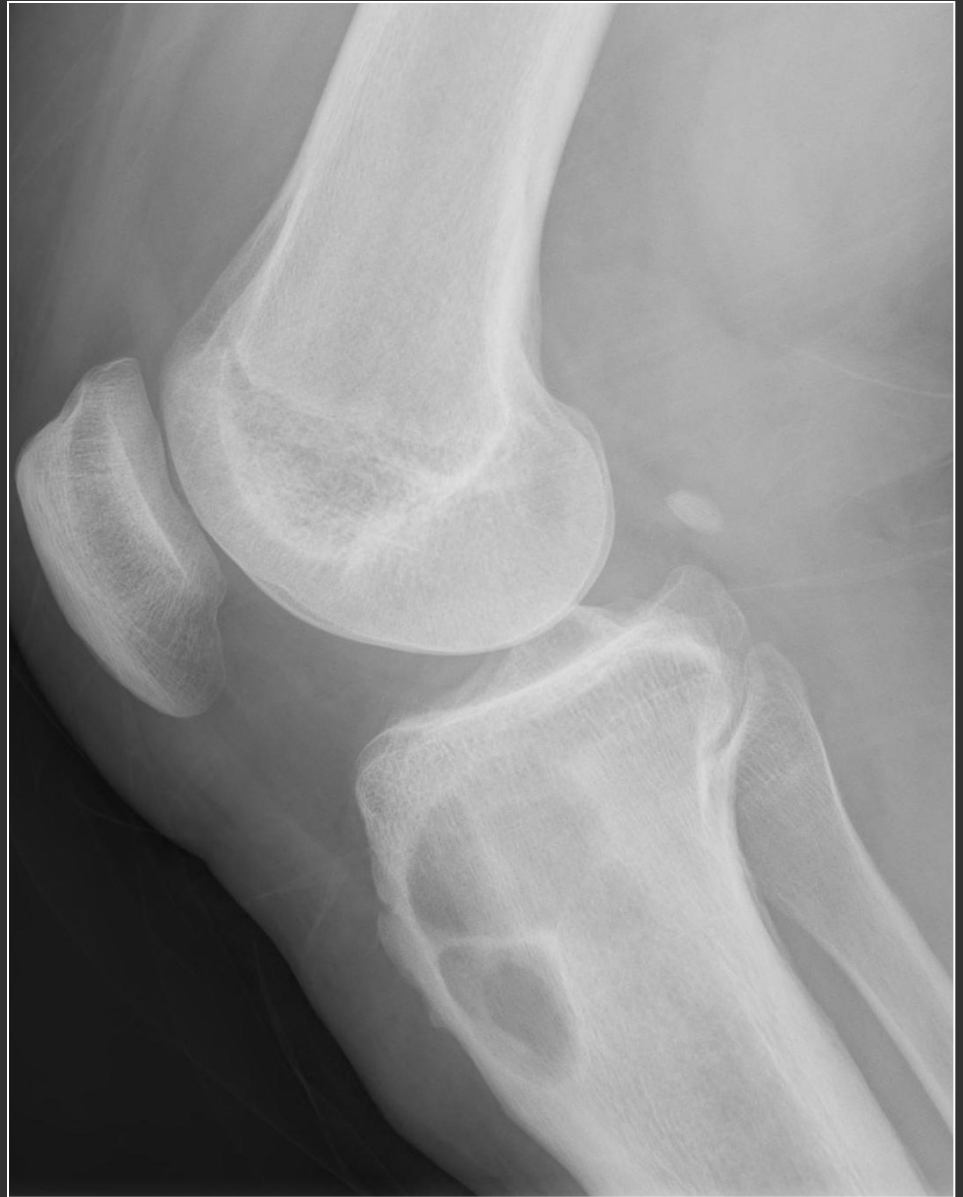
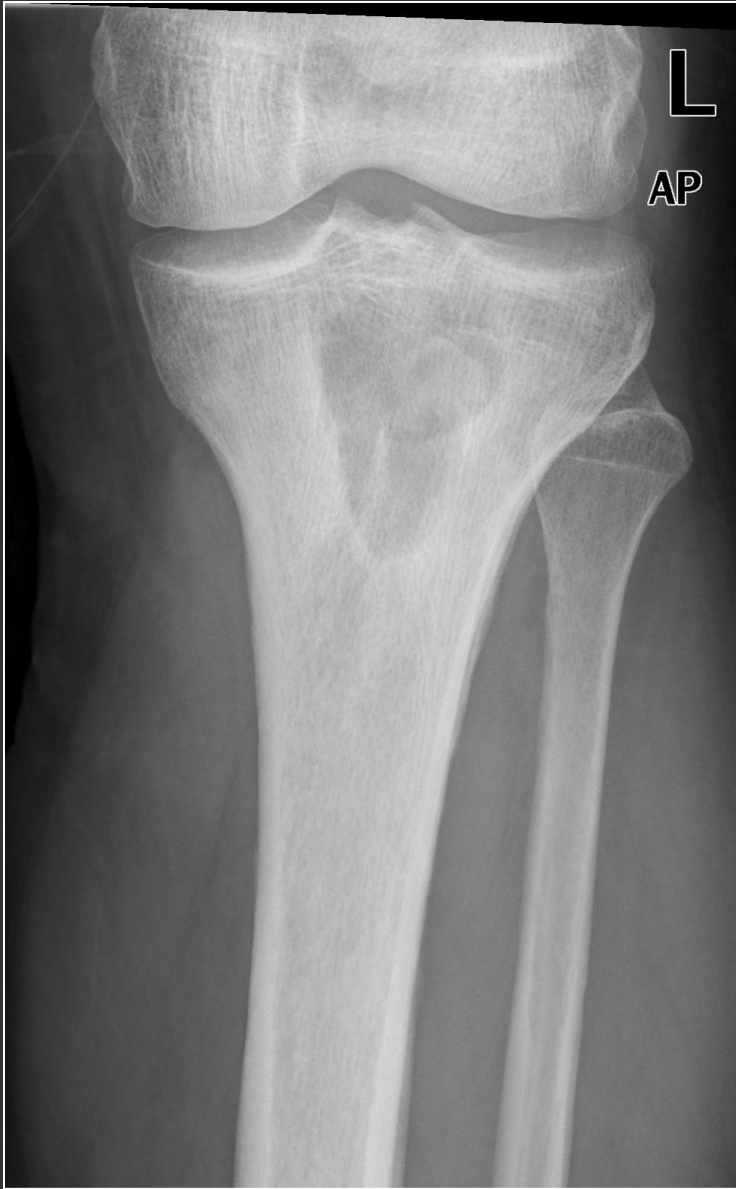
CT – This case is to show typical features of chronic osteomyelitis: **bone sequestrum** (*arrows*), **cloaca** (*circle*) and marked thickened cortex. Remember, if you see a bony sequestrum in a lytic epiphyseal lesion only two diagnosis should be considered: one is osteomyelitis (like this case) and the other one is eosinophilic granuloma.

OSTEOMYELITIS - CASE 2 – Woman 77 years

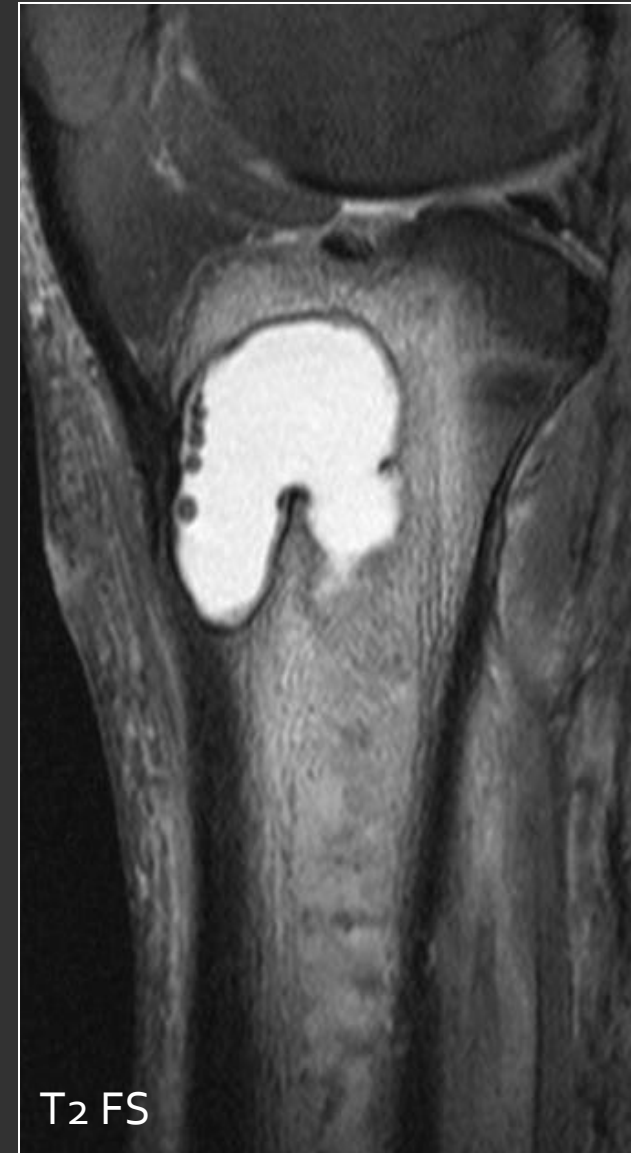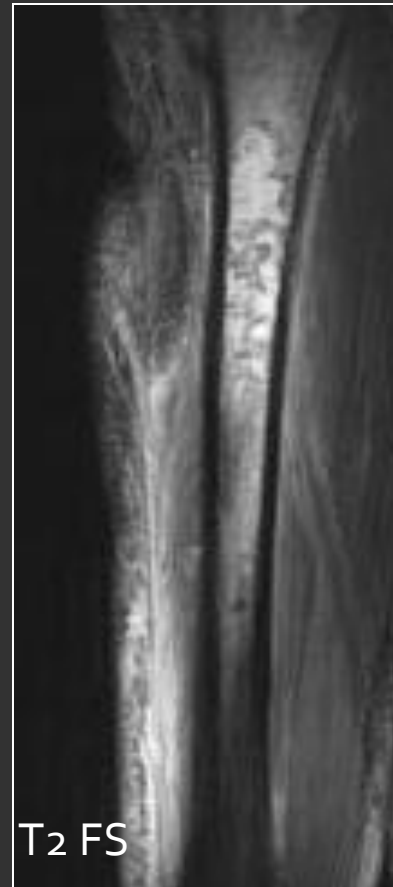
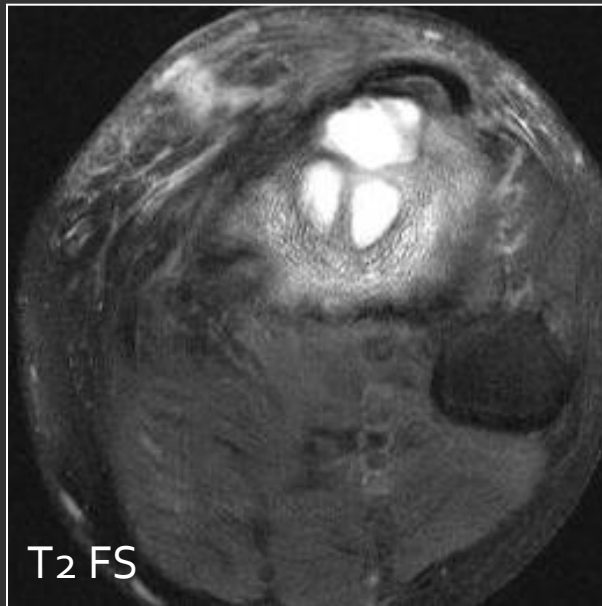
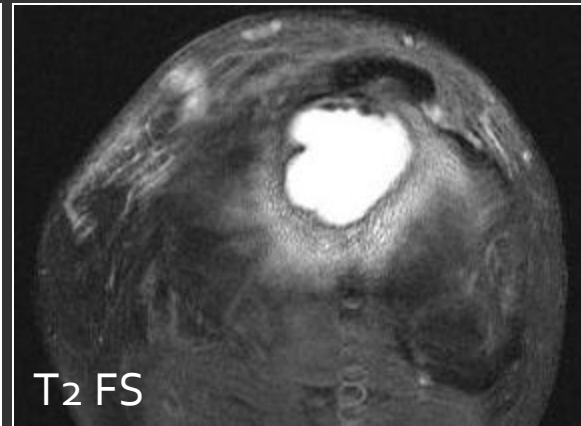

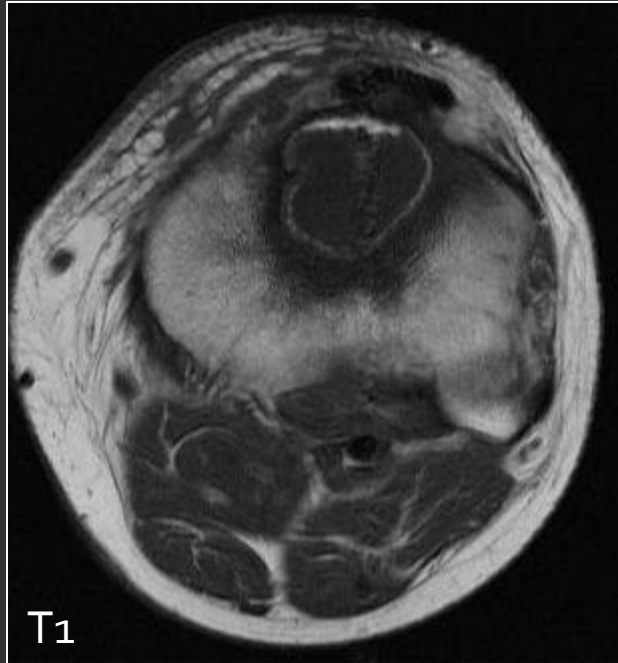
X-Ray and CT – Chronic osteomyelitis demonstrating a prominent host reaction, including a thickened cortex and variable mixtures of lucency and density.

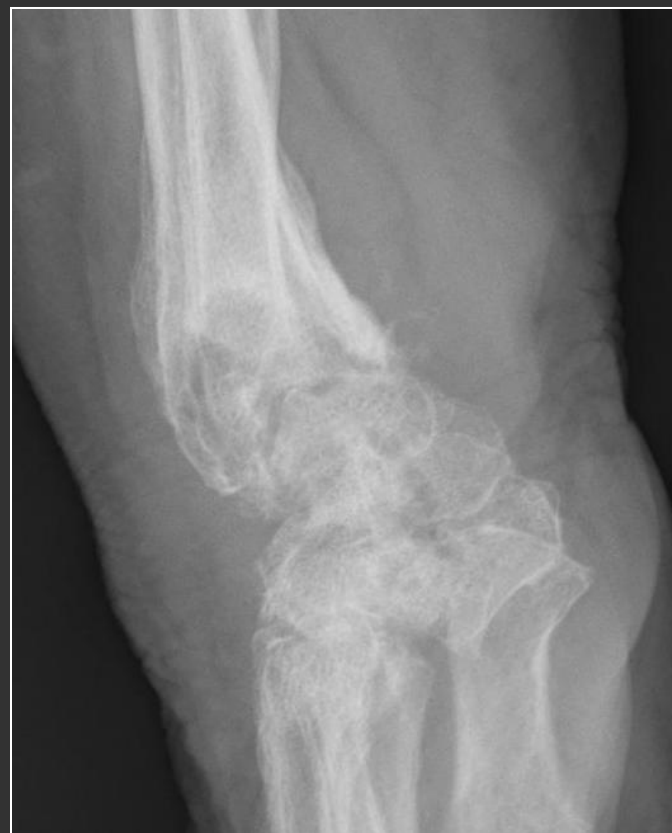
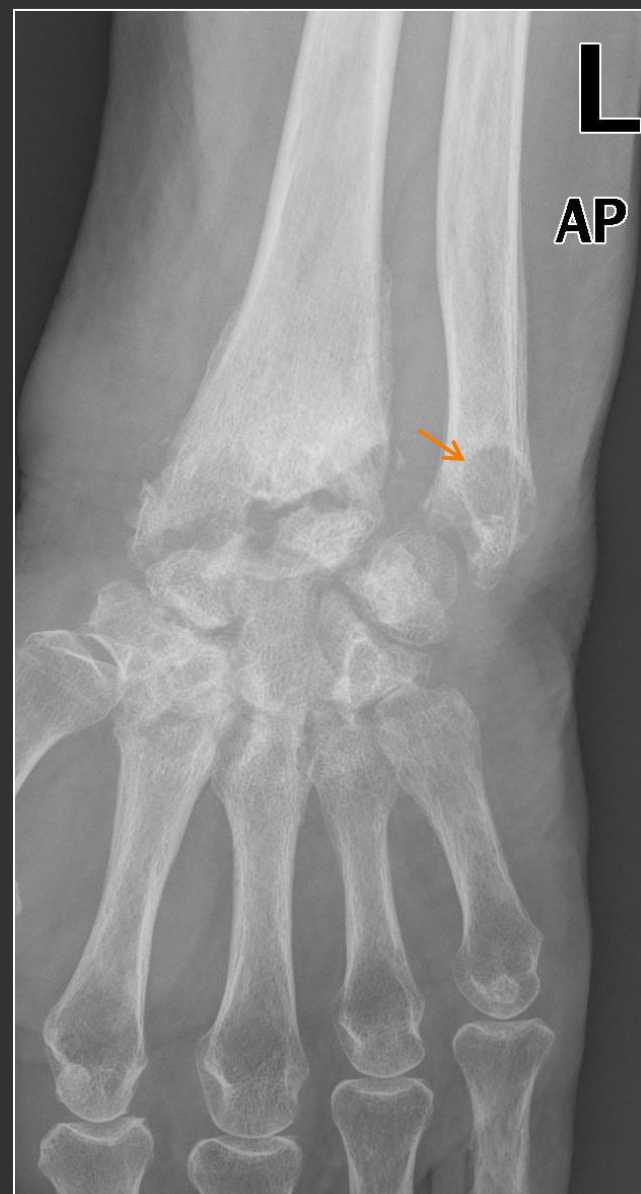
X-Ray – Well defined lytic lesions predominantly in metaphysis, but also involving the epiphysis. There is a thick and fuzzy sclerotic margin.

OSTEOMYELITIS - CASE 3 – man 46 years



OSTEOMYELITIS - CASE 4 – Woman 65 years



X-Ray - This patient has septic arthritis of radio-carpal joint (osteopenia, decreased joint space, irregular joint surfaces, bone erosions and destruction and wrist soft tissue thickening). The lytic lesion of distal epiphysis of ulna (*arrows*) was a focus of osteomyelitis that developed by means of contiguous spread. **Remember joint involvement can be a clue to the etiology of a lytic epiphyseal lesion.**

SUBCHONDRAL CYSTS

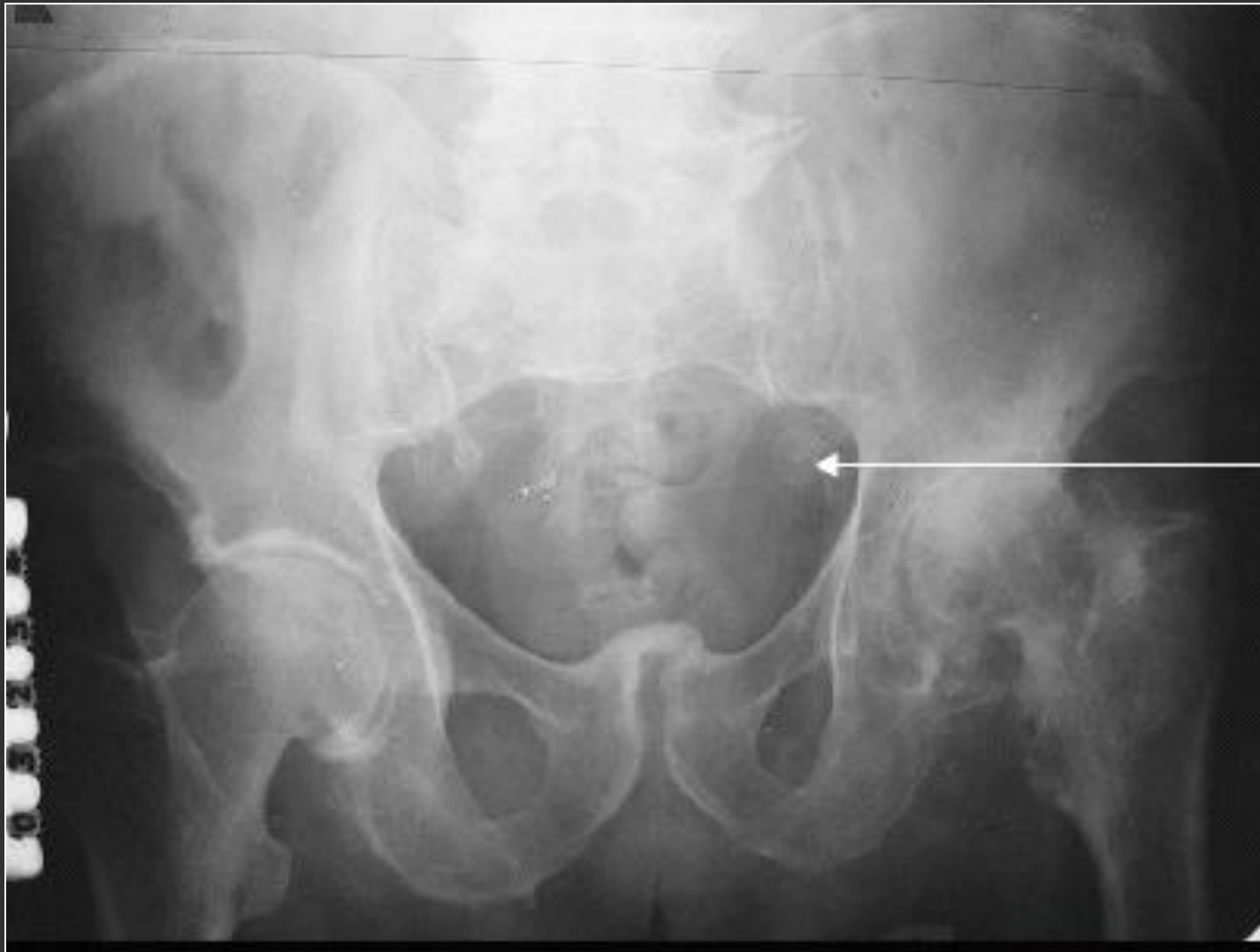- Almost any artropathy can cause subchondral cysts (geodes)
- Subchondral cysts caused by inflammatory joint disease are due to pannus intrusion in subchondral bone
- Subchondral cysts caused by noninflammatory joint disease are due to liquefaction of subchondral bone following pressure necrosis, or synovial intrusion at joint surfaces worn down to bone
- Sharp, sclerotic borders suggest a noninflammatory process, or an inactive inflammatory process

SUBCHONDRAL CYSTS

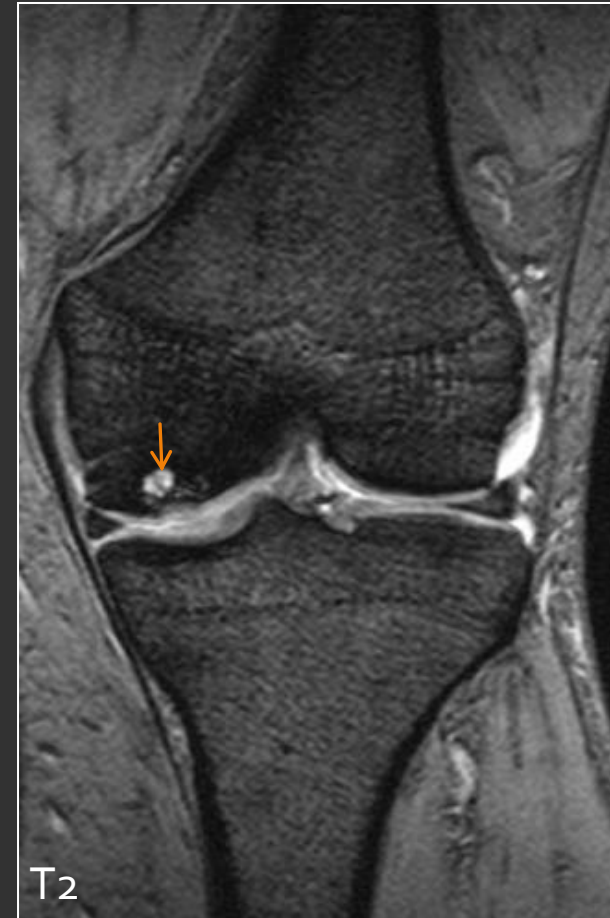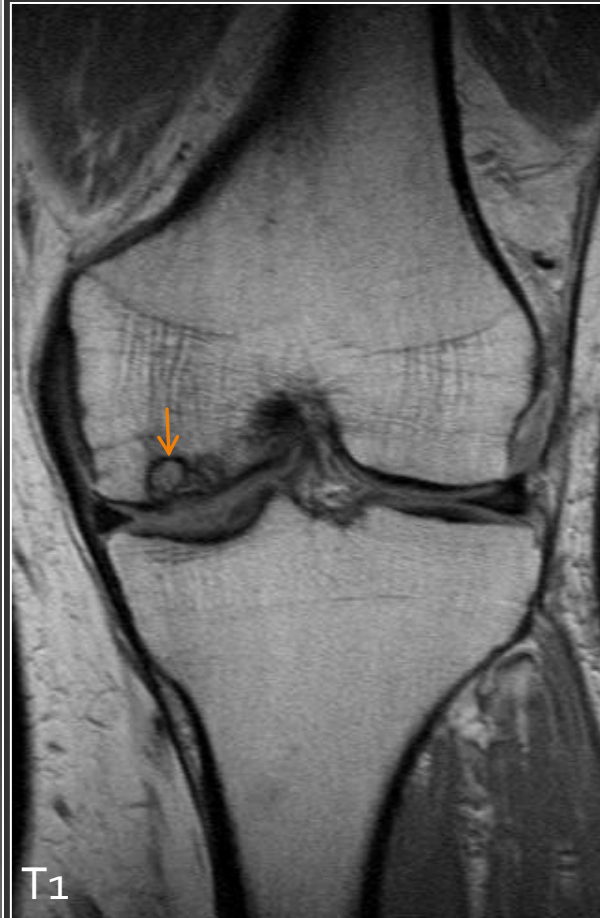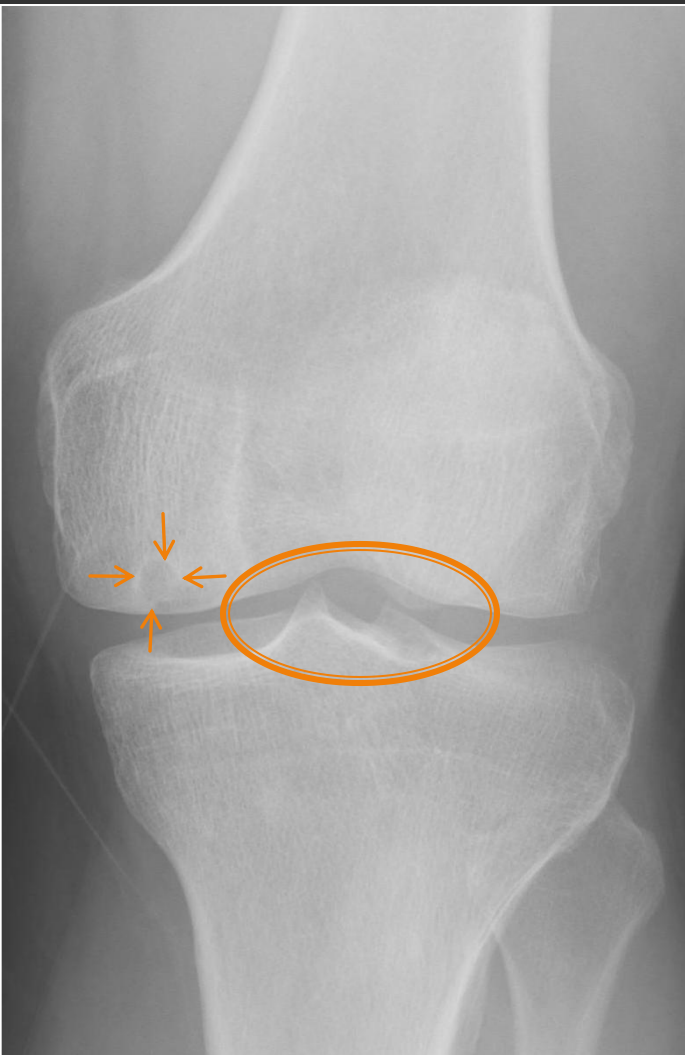
- Examples of arthropathy that cause subchondral cysts:
 - Degenerative joint disease (Osteoarthritis)
 - Calcium pyrophosphate dihydrate crystal disease
 - Seronegative spondyloarthropathies
 - Gout
 - Pigmented villonodular synovitis
 - Synovial osteochondromatosis
 - Neuropathic joint
 - Rheumatoid arthritis
 - Avascular necrosis

SUBCHONDRAL CYSTS

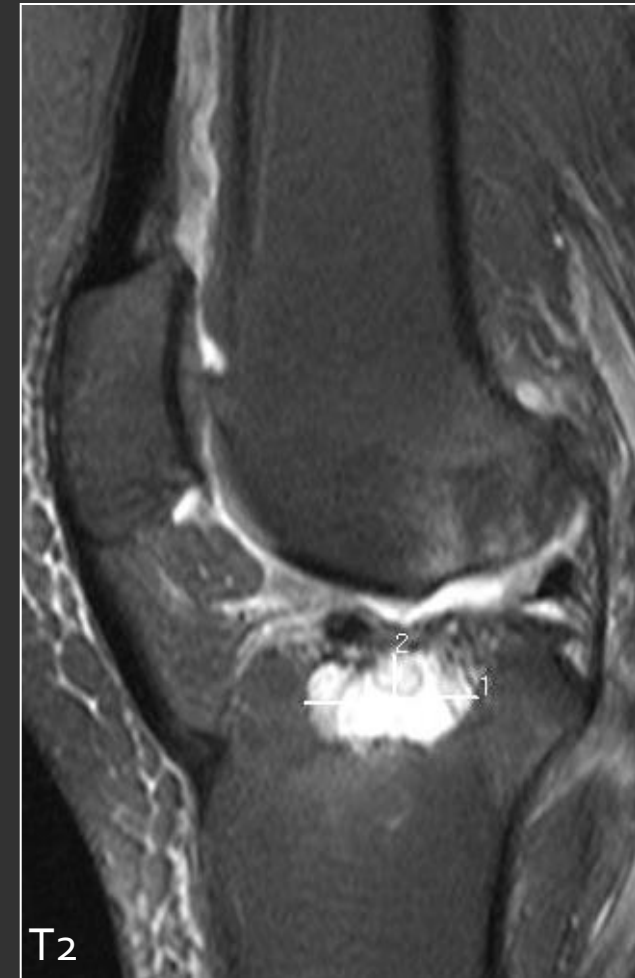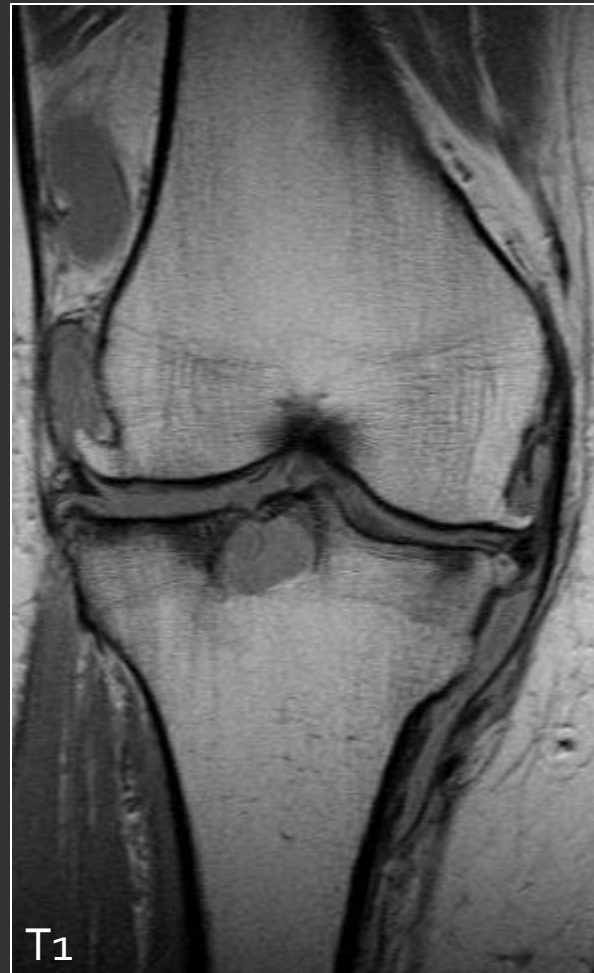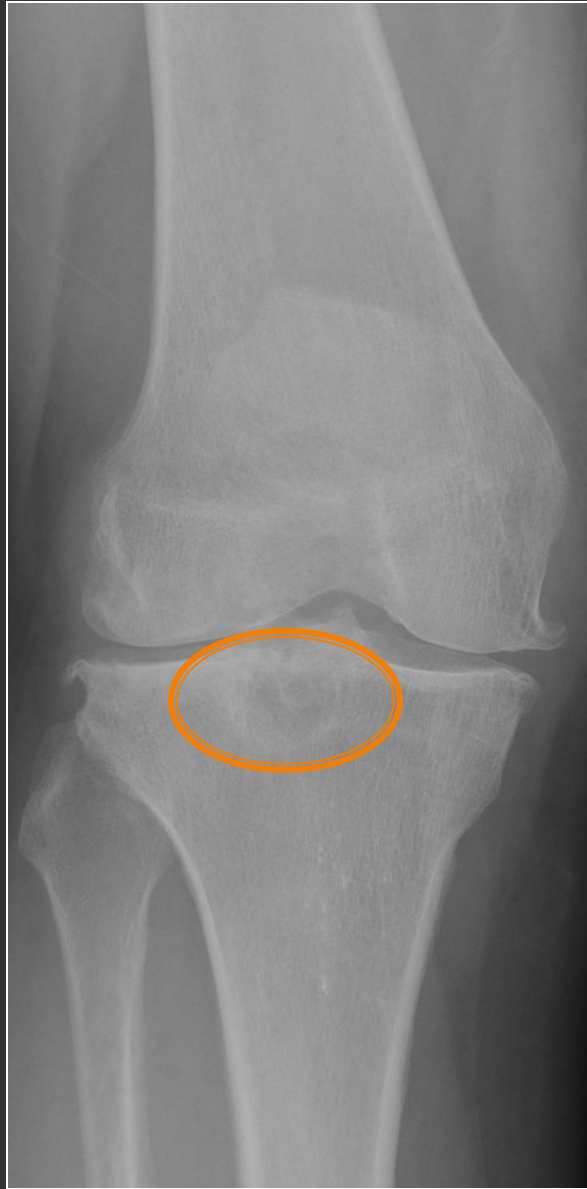
- Geodes almost always are associated with additional findings, such as joint space narrowing, osteopenia or sclerosis periarticular, subluxations and other deformities, osteophytes, enthesophytes, erosions...
- However on occasion the additional findings of articular disease are subtle and biopsy may be necessary



Pelvis X-Ray – There are small rounded radiolucent images on left femoral head. There are also hallmarks of hip osteoarthritis with subchondral sclerosis, osteophytes and joint space narrowing (with superior migration of the femoral head); hence the radiolucent images are subchondral cysts and biopsy is not necessary. Arrow points to vascular calcifications.

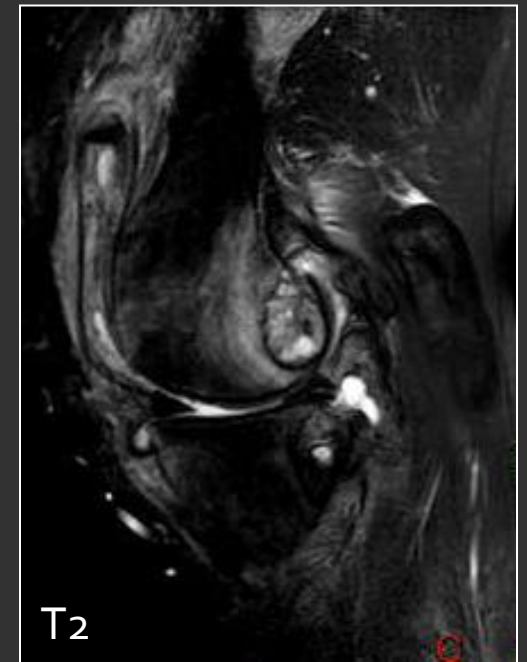
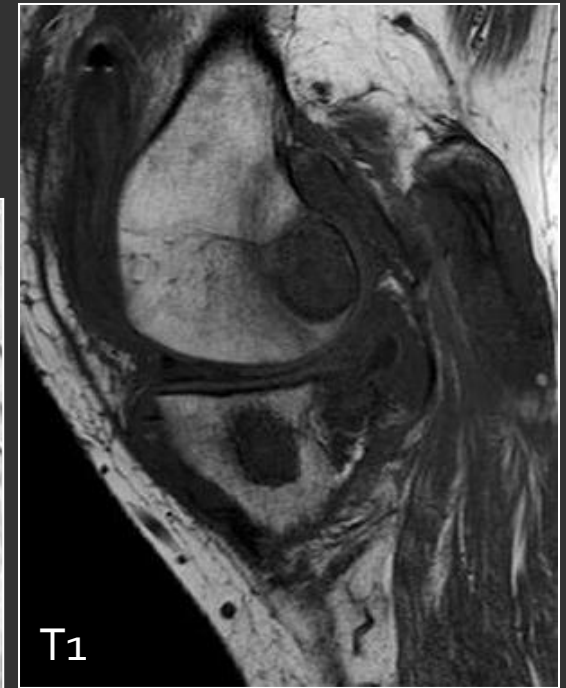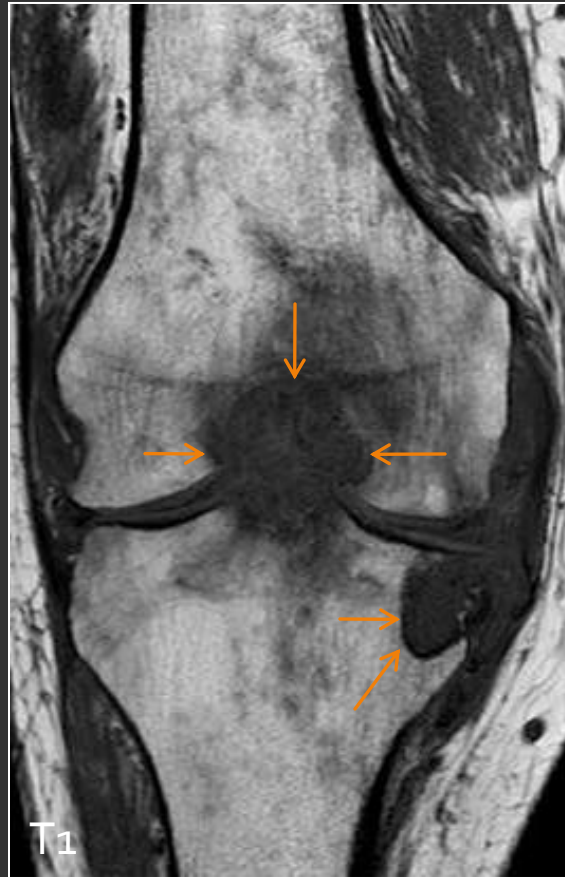
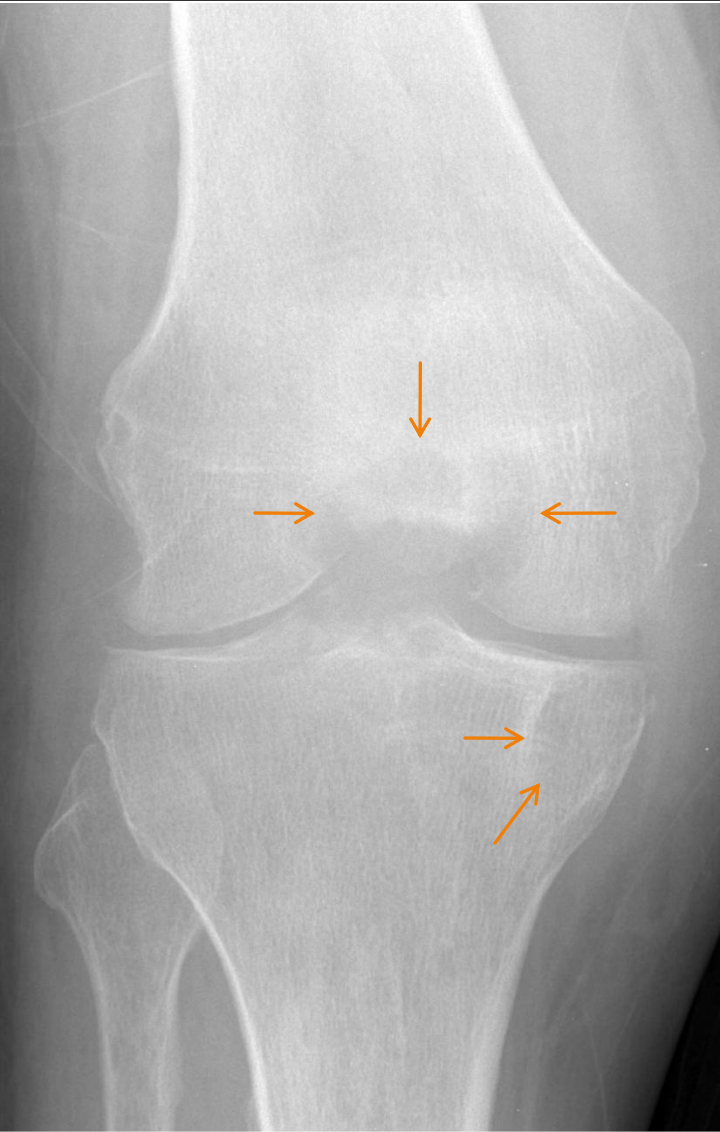


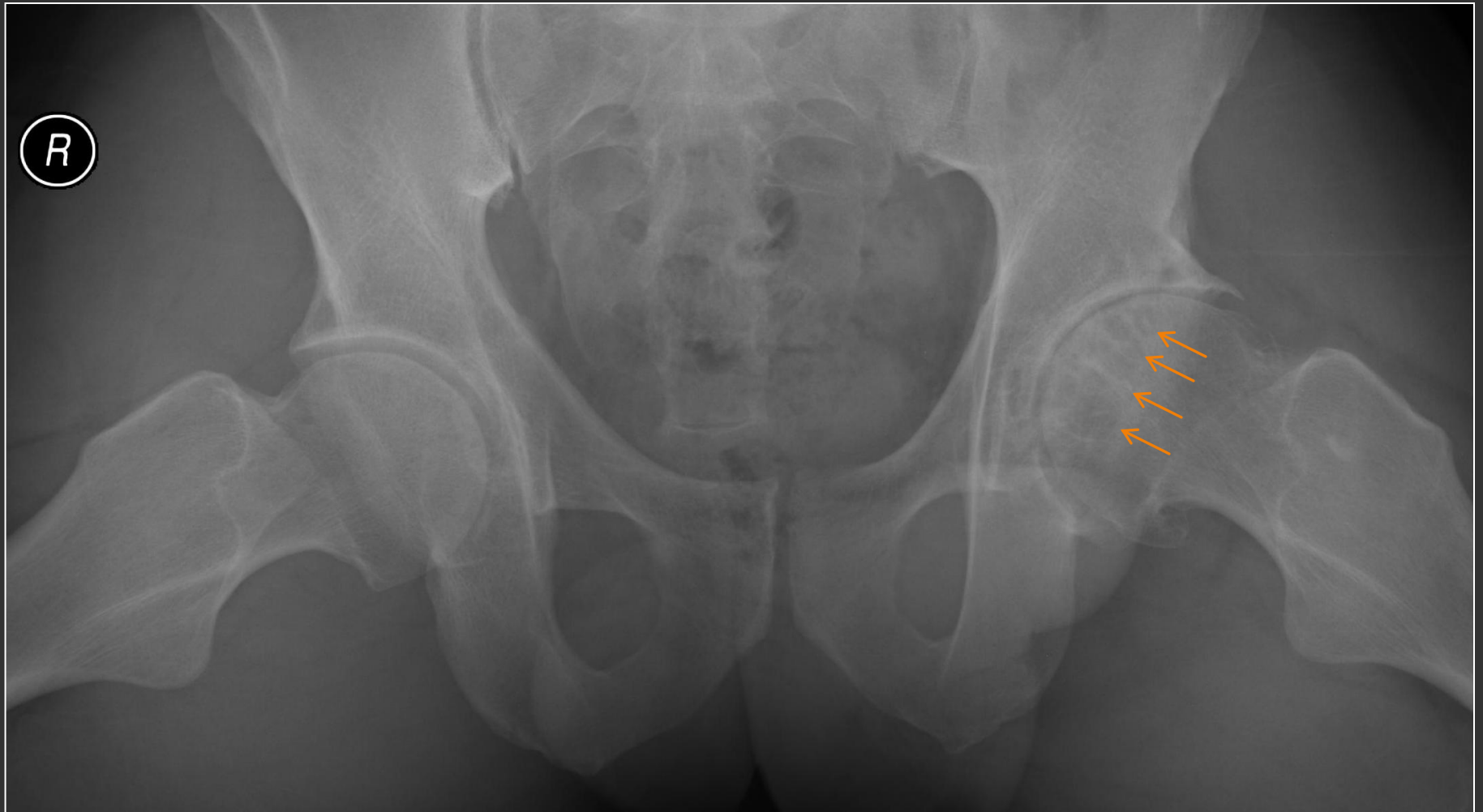
X-Ray and MRI – Very small lytic lesion (*arrows*) of left femur's medial condyle with sclerotic margin. Mild osteoarthritis was believed to be present because there is osteophytes of tibia's intercondylar tubercles (*circle*); so this was believed to be a subchondral cyst or geode. MRI confirmed a small geode (*arrows*), low signal on T1 and high signal on T2.



X-Ray and MRI – This case is very similar to case 2, except that it is much more straightforward. There is a relatively large (2 cm) subchondral cyst located at tibia's epiphysis (*circle*) associated with evident degenerative joint disease (subchondral sclerosis, tibial and femoral osteophytes and joint space narrowing).

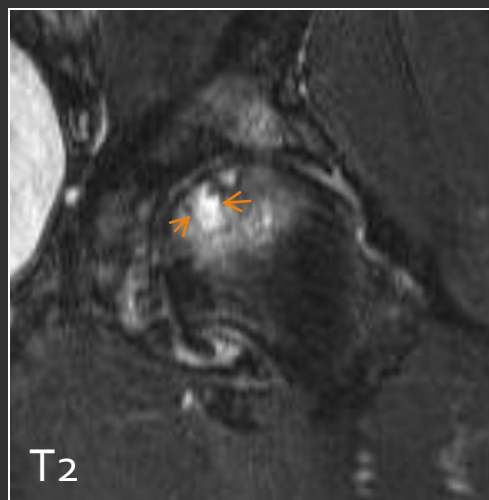
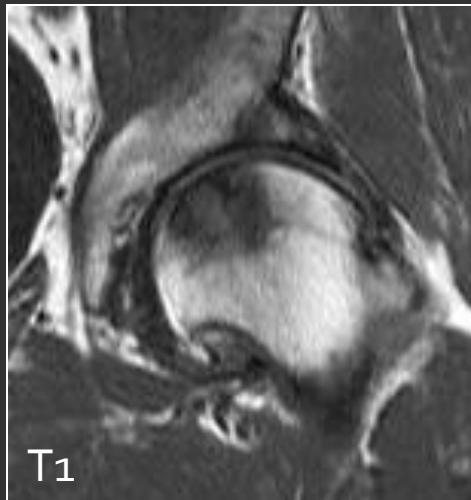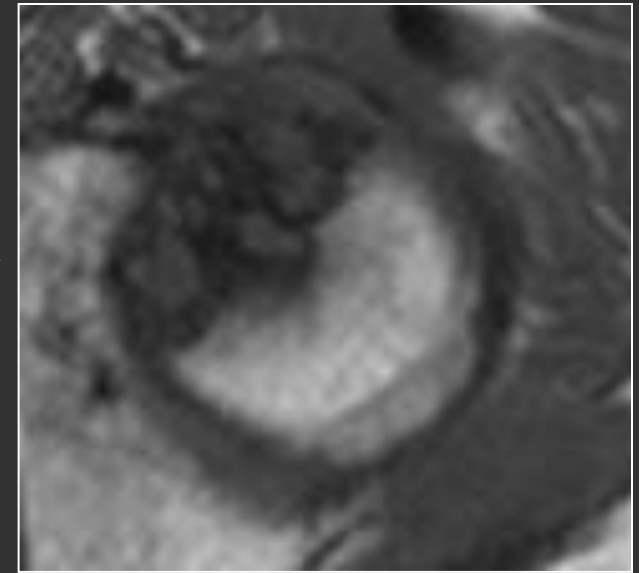
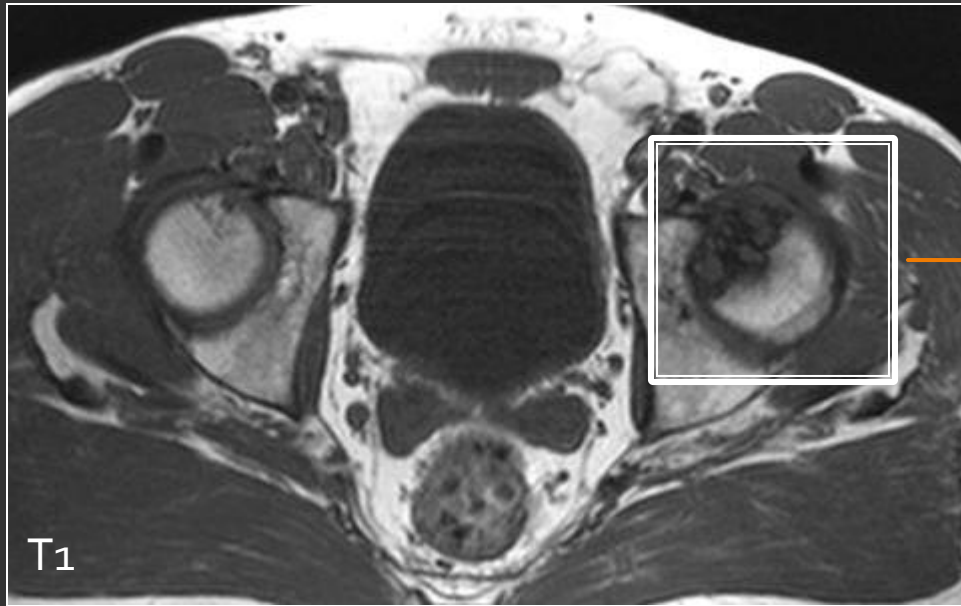
SUBCHONDRAL CYSTS - AMYLOIDOSIS – CASE 4





X-Ray – Several ill-defined radiolucent images in the head of left femur. There are also signs of degenerative joint disease, but the patient had subacute hip pain and was taking prednisolone, so avascular necrosis cannot be excluded.

SUBCHONDRAL CYSTS - AVASCULAR NECROSIS – CASE 5

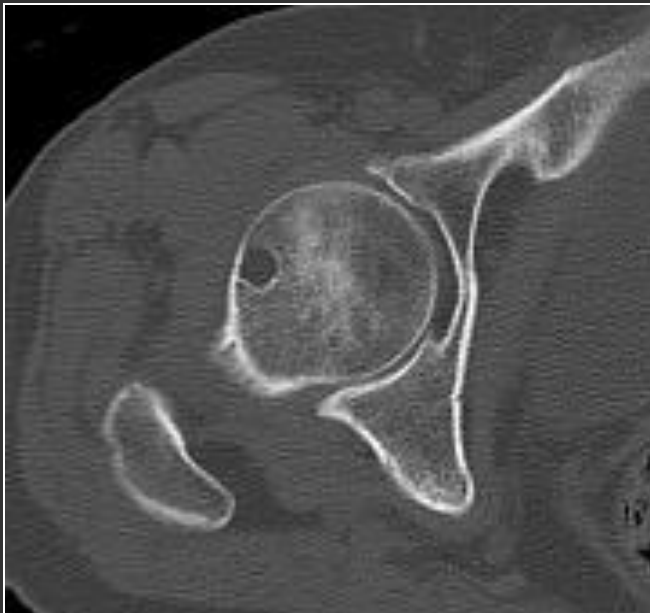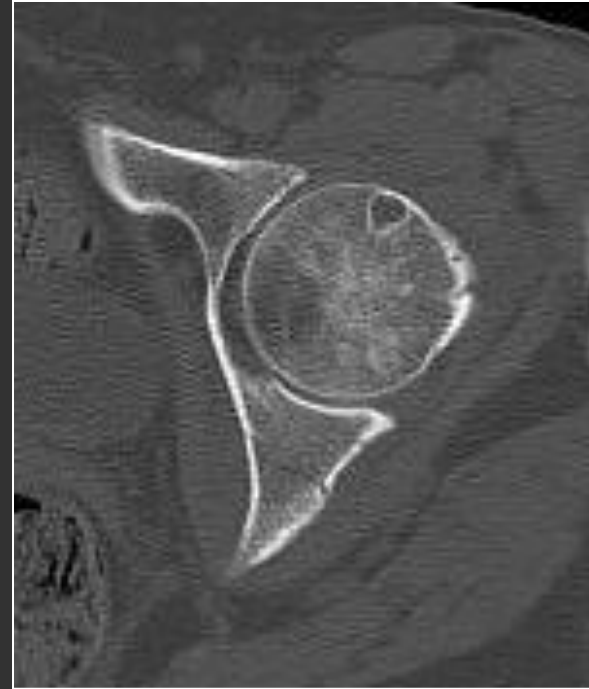
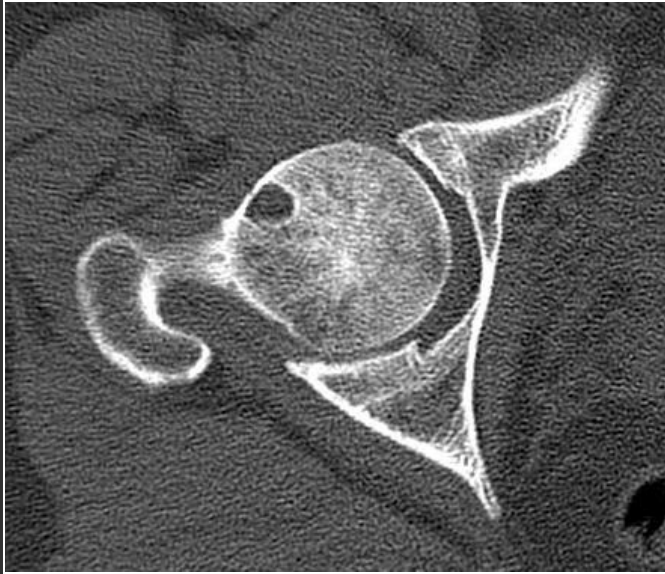


RMI shows loss of normal femur head morphology, with mild flattening. There is bone marrow edema and the classic double-line sign (*arrows*), a sign that is highly specific for avascular necrosis. Don't forget: avascular necrosis is a well know cause of subchondral cysts.

INTRAOSSEOUS GANGLION CYST

- Benign lesions located in the subchondral bone adjacent to the joint
- Usually found incidentally in young adults
- Surrounded by a sclerotic border on radiographs and are smaller than the average epiphyseal tumor
- Favored sites include the proximal tibia and the medial malleolus
- At RMI they are of homogeneous fluid signal intensity, but may be loculate. After IV gadolinium, a peripheral rim of enhancement due to surrounding connective tissue is common

INTRAOSSSEUS GANGLION CYST - EXAMPLES



CT – Small radiolucent images located at femur head of three young patients. These lesions are small and have a sclerotic margin. These patients were asymptomatic, there were no signs of degenerative joint disease (or other articular process) and small size of lesion argues against the typical primary lytic epiphyseal tumor.

LYTIC EPIPHYSEAL LESION

The four radiographic criteria for Giant Cell Tumor are positive (*)

GIANT CELL
TUMOR most
probable

Age > 40 years

Always consider:
Metastases
Multiple Myeloma

You can exclude:
Chondroblastoma
Eosinophilic Granuloma
Aneurysmal Bone Cyst

Signs of joint involvement

Subchondral
Cyst

Osteomyelitis can have virtually any radiographic appearance, in a patient of any age !